



## PROCEEDINGS OF THE 12<sup>th</sup> WORLD RABBIT CONGRESS

Nantes (France) - November 3-5, 2021

ISSN 2308-1910

### Session **PATHOLOGY & HYGIENE**

***Makhlouf C., Khaldoun Oularbi H., Zerrouk N.H., Bokreta S., Oularbi Y. , Tlili T.,  
Aoun R., Daoudi-Zerrouki N.***

BENEFICIAL EFFECTS OF ASCORBIC ACID AGAINST NEPHROTOXICITY  
INDUCED BY IVERMECTIN REPEATED HIGHDOSE THERAPY IN RABBITS  
(*ORYCTOLAGUS CUNICULUS*)

**Full text of the communication**

+

**Poster**

#### *How to cite this paper*

Makhlouf C., Khaldoun Oularbi H., Zerrouk N.H., Bokreta S., Oularbi Y. , Tlili T.,  
Aoun R., Daoudi-Zerrouki N., 2021 Beneficial effects of ascorbic acid against  
nephrotoxicity induced by Ivermectin repeated highdose therapy in rabbits  
(*Oryctolagus cuniculus*). Proceedings 12th World Rabbit Congress - November 3-5 2021 - Nantes,  
France, Communication P-26 , 4 pp. + presentation

## BENEFICIAL EFFECTS OF ASCORBIC ACID AGAINST NEPHROTOXICITY INDUCED BY IVERMECTIN REPEATED HIGH-DOSE THERAPY IN RABBITS (*ORYCTOLAGUS CUNICULUS*)

Makhlouf C.<sup>1,2\*</sup>, Khaldoun Oularbi H.<sup>1,2</sup>, Zerrout N.H.<sup>1</sup>, Bokreta S.<sup>1</sup>, Oularbi Y.<sup>3</sup>,  
Tlili T.<sup>2</sup>, Aroun R.<sup>2</sup>, Daoudi-Zerrouki N.<sup>2</sup>

<sup>1</sup> Department of Biology, Faculty of Nature and Life Sciences, University Blida 1, BP 270, Soumaa, Blida, Algeria

<sup>2</sup> Natural Resources Laboratory, University Mouloud Mammeri, BP 15017, Tizi-Ouzou, Algeria

<sup>3</sup> National Higher School of Agronomy, Algiers, Algeria

\*Corresponding Makhlouf chahrazed: chahrazedmakhlouf@yahoo.com

### ABSTRACT

Ivermectin (IVM) is a lipophilic anthelmintic drugs widely used for the control of internal and external parasites in both human and veterinary medicine. The present experiment pertains to the protective role of ascorbic acid (AA) against biochemical and histopathological nephrotoxicity induced by IVM repeated high dose therapy in male young rabbits (*Oryctolagus cuniculus*). Twenty rabbits were divided into four groups of five: Control, IVM, IVM + AA by gavage, IVM + AA supplemented in food groups. The creatinine, uric acid and urea levels were measured from the plasma while the kidneys tissues samples were used for histopathological investigations. IVM alone induced a significant ( $p < 0.05$ ) decrease in the body weight and body weight gain and a significant increase in both left and right kidney weights. This study showed a disruption of renal biochemical parameters with a statistically significant increase in creatinine levels in IVM group compared to control group. However, co-administration of AA moderately improved this biochemical parameter. Light microscopic observations revealed variable signs of renal toxicity in the IVM group where the renal cortex exhibits serious pathological changes, including vascular changes, hemorrhages, mononuclear infiltrating cells and degeneration of tubular cells. In the other hand, the AA treatment showed significant improvement when co-administered orally with IVM. These results suggest that AA has beneficial influences in neutralizing the toxic effects of IVM for the biochemical and histological parameters of the kidney of rabbits.

**Key words:** Ivermectin, Ascorbic acid, Biochemical parameters, Histopathology, Rabbit.

### INTRODUCTION

In veterinary medicine, macrocyclic lactones (MLs) enjoy a position of prominence in the control of parasites and are probably the most widely used anti-parasitic agents in the treatment of food producing animals, poultry, aquaculture and crops. Ivermectin was the first commercially available endectocide macrocyclic lactone (ML), discovered in the mid-1970s and used in veterinary and humans clinical medicine (Omondi *et al.*, 2017; Campbell, 2016). Since its discovery, a number of alternative products such abamectin, doramectin, emamectin, eprinomectin, moxidectin, milbemycin and selamectin, have been marketed (Campbell, 2012). Guzzo *et al.* (2002) reported that ivermectin at doses up to 10 times the highest FDA-approved dose of 200 µg/kg is generally well tolerated, with no indication of associated CNS (central nervous system) toxicity. Nonetheless, at higher concentrations, IVM has a broad range of effects in many different organisms and repeated administration of different doses of IVM induced histopathological alterations in liver (AL-Jassim *et al.*, 2015), kidneys, testis (Elzoghby *et al.*, 2015) and brain tissues (Li *et al.*, 2013) of rabbit, rat and pigeon respectively. Recently, protective effects of natural antioxidants against toxicity of various agents are the focus of interest. Some antioxidant can be administered with ivermectin to improve its side effects such as alpha lipoic acid (ALA), vitamin E and K, selenium (Ali, 1990; Behera *et al.*, 2011) and vitamins A, D, E, H and C (Singh *et al.*, 2012). Ascorbic acid (Vitamin C) is a water-soluble antioxidant which have potential protective effects on oxidative stress and environmental toxicities (Mandl *et al.*, 2009; AL-Jassim *et al.*, 2015). Beneficial effects of Vitamin C in attenuating avermectin-toxicity are well-known (Khaldoun Oularbi *et al.*, 2017; Omshi *et al.*, 2018). Thus, the

present study first describes the toxic effect of repeated subcutaneous injections of ivermectin on the kidneys' histopathology and the renal biochemical parameters in young rabbits of (*Oryctolagus cuniculus*) strain, afterward, it investigates the beneficial effects of ascorbic acid on ivermectin repeated high-dose therapy in rabbits.

## MATERIALS AND METHODS

### Animals and experimental design

Twenty healthy male young Algerian rabbits (*oryctolagus cuniculus*), 4–5 weeks-old with body weight (BW) ranging from 850 to 950 g were used in this study. Rabbits were obtained from a state breeding unit of Djebba (Tizi-Ouzou) and kept for experimentation in the CRD of Saidal, Oued semar, Algeria. Rabbits were acclimated to the laboratory conditions for 2 weeks before treatment and had free access to a commercial pellet diet and water *ad libitum*. Animals were divided into four groups of five. A control group and three groups treated subcutaneously with a high dose (2 mg kg<sup>-1</sup> of body weight) (Lu *et al.*, 2017) of ivermectin (3 times / week) for three consecutive weeks, including one group is treated only with ivermectin (IVM group); the second group is co-treated orally with ascorbic acid by gavage (IVM group + AAg (AA: 20 mg / kg / bw)) and the third group is co-treated with ascorbic acid supplemented with food (group-IVM + AAf (200 mg / kg / food)), ascorbic acid is administered with a mean interval of 12 h after IVM injection. Animals were weighed daily and the dose of ivermectin and ascorbic acid was adjusted accordingly.

### Chemical Analyses

At 14 and 21 days of the experiment, blood samples were collected with heparinized syringes from the ear vein for biochemical evaluations. The following renal parameters: creatinine, uric acid and urea, were assessed in plasma using a commercially available spectrophotometric enzymatic kit (Biolabo, France) and analyzed by an auto-analyzer (Hitachi 912) instrument (Roche Diagnostics, Mannheim, Germany). At the end of the experiments, the rabbits were euthanized by cervical decapitation, and kidneys were carefully dissected out from all rabbit groups and weighed in grams, then the kidneys were fixed in 10% neutral formalin buffer, processed through graded alcohols and xylene and embedded in paraffin blocks. Kidney sections were cut and stained with haematoxylin and eosin for histopathological studies.

### Statistical Analysis

Statistical analysis was performed using Statistica version 10.0 (Stat Soft Inc., Tulsa, Oklahoma, USA) and Microsoft Excel. Data were calculated using one-way analysis of variance followed by the Duncan's post hoc tests. Data were expressed as the mean  $\pm$  SD. A p-value < 0.05 was considered as the level of significance

**Table 1:** Effects of IVM and IVM + AA treatments on body weight (BW), body weight gain (BWG) (%) and absolute and relative kidney weights in rabbits, 21 days after treatment

Period / Groups		Control	IVM	IVM + AAg	IVM + AAf
experimentation	Initial BW (g)	1347 $\pm$ 22	1329 $\pm$ 20	1351 $\pm$ 26	1326 $\pm$ 36
	Final BW (g)	1806 $\pm$ 63	1586 $\pm$ 71*	1693 $\pm$ 47.*	1676 $\pm$ 1*
	% BWG	34.10 $\pm$ 0.47	19.28 $\pm$ 0.8*	25.31 $\pm$ 0.77 *	26.3 $\pm$ 0.82 *
	RK weight (g)	absolute	5.7 $\pm$ 0.9	6.8 $\pm$ 1.3 *	6.1 $\pm$ 0.7
		relative	0.3 $\pm$ 0.0	0.4 $\pm$ 0.1 *	0.3 $\pm$ 0.0
	LK weight (g)	absolute	6.0 $\pm$ 0.7	6.7 $\pm$ 1.4 *	6.3 $\pm$ 0.7
		relative	0.3 $\pm$ 0.0	0.4 $\pm$ 0.1 *	0.4 $\pm$ 0.0

IVM: Ivermectin; AA: Ascorbic Acid; AAg: Ascorbic Acid by gavage; AAf: Ascorbic Acid supplemented in food

RK: right kidney; LK: left kidney

Results are given as a mean  $\pm$  SD for five rabbits in each group.

IVM and AA co-treated groups vs. control group: \* p < 0.05.

## RESULTS AND DISCUSSION

### Effect of treatments on body and kidney weights

As shown in the Table 1, in the IVM treated group, the body weight and the percentage of body weight gain were significantly (p<0.05) decreased compared to control. This decrease of body weight might be due to the reduced

food intake as a result of loss of appetite of the young male rabbits. Ivermectin alone induced a significant increase in the absolute and relative weights of both right and left kidneys. These findings are in accordance with those obtained by authors after avermectin administration (Lu *et al.*, 2017; Khaldoun Oularbi *et al.*, 2015; AL-Jassim *et al.*, 2015; ElZoghby *et al.*, 2015). Interestingly, the co-administration of ascorbic acid orally in water or in food to IVM rabbits was capable of protecting against the lowered body weight and increased kidney weights and overall health of rabbits.

### Effects of treatments on plasma renal parameters

Kidney damage is caused by excessive exposure to drugs and toxins. As shown in Table 2, IVM induced nephrotoxicity as demonstrated by the elevation of kidney biomarkers in plasma. Only creatinine level

**Table 2:** Effects of treatments on plasma levels of kidney biochemical markers in rabbits from control, IVM and IVM + AA-treated groups (IVM + AAg, IVM + AAF)

Period	Blood chemistry parameters	Experimental groups			
		Control	IVM	IVM + AAg	IVM + AAF
14 days	Creatinine (mg/dl)	7.17±0.02	10.9±0.01*	7.5±0.37	8.85±0.14*
	Urea (mg/dl)	0.27±0.0	0.32±0.0	0.24±0.01	0.29±0.01
	Uric acid (mg/dl)	4.6±0.0	5.1±0.0	5.0±0.6	4.9±0.4
21 days	Creatinine (mg/dl)	7.24±1.69	8.58±0.88*	7.38±0.51	7.72±1.3
	Urea (mg/dl)	0.27±0.01	0.34±0.02	0.25±0.02	0.30±0.03
	Uric acid (mg/dl)	4.6±0.0	5.2±0.0	4.6±1.4	4.7±0.3

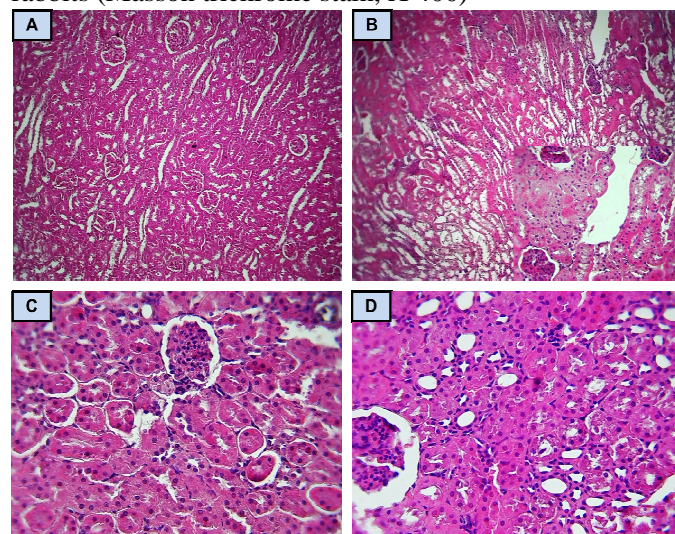
IVM: Ivermectin; AA: Ascorbic Acid; AAg: Ascorbic Acid by gavage; AAF: Ascorbic Acid supplemented in food

Results are given as a mean ± SD for five rabbits in each group.

IVM and AA co-treated groups vs. control group: \* p < 0.05.

was significantly increased ( $P < 0.05$ ) in response to IVM treatment compared to those of control rabbits. Malfunction in glomerular filtration results in the retention of molecules including creatinine, and this may be responsible for its high plasma level in IVM group. Those results corroborated with the findings of previous studies (Arise and Malomo, 2009; El-Far, 2013, Khaldoun Oularbi *et al.*, 2015). In contrast, this parameter was reduced when IVM treated-rabbits were co-administered with ascorbic acid supplemented with food compared to rabbits administered with IVM alone and compared to the controls. AL-Jassim *et al.* (2016) reported that treatment of rabbits with 1 mg/kg b.w. of ivermectin plus vitamin C showed a significant decrease in serum urea, supporting the action of vitamin C as a scavenger of free radicals.

**Figure 1:** Histology of the renal parenchyma of control (A), IVM (B), IVM+AAg (C) and IVM+AAf (D) treated rabbits (Masson trichrome stain, X 400)



### Effects of treatments on kidney histological structure

In the control group, the kidney show normal histology with normal appearance of renal corpuscles, glomeruli, surrounded by Bowman's spaces and cortical tubules with distal and proximal convoluted tubules (Figure 1: A). In IVM group, kidney cortex show pathological alterations, including vascular alterations, hemorrhages, mononuclear infiltrating cells and degeneration of the tubular cells

(Figure 1: B). The present result is in accordance with many work's which demonstrated that the repeated administration of either therapeutic or double therapeutic doses of ivermectin induced severe degenerative changes and necrosis in some parenchymatous organs (El-Far, 2013; Li *et al.*, 2013 ; Elzoghby *et al.*, 2015). These pathological changes were more ameliorated in IVM + AAg group (Figure 1: C) compared to IVM + AAF group (Figure 1: D). From our results we can assume that renal histological damages of ivermectin are mainly attributed to oxidative stress increase since the effects were largely prevented by ascorbic acid supplementation. Previous studies have also shown the curative and antioxidant efficiency of AA and other vitamins against avermectin toxicity (Behera *et al.*, 2011; AL-Jassim *et al.*, 2016; Khaldoun Oularbi *et al.*, 2017; Omshi *et al.*, 2018).

### CONCLUSIONS

The findings presented from this study have revealed that Ivermectin repeated high-dose therapy in rabbits may cause impairment of the renal biochemical and histological parameters and that vitamin C co-treatment could reduce the degree of Ivermectin toxicity. Careful application should be considered when using Ivermectin on wide scale in rabbits and others farm animals.

### REFERENCES

- Ali B.H. 1990. The effect of ivermectin on some haematological indices in rabbits: influence of vitamin K treatment. *Clinical and experimental pharmacology and physiology*, 17(10), 735-738.
- Al-Jassim K.B., Jawad A.A.D.H., Al-Masoudi E.A. 2015. Effects of Ivermectin on Lipid Profiles, Antioxidant Enzymes and Proteins with the Beneficial Effects of Vitamin C in Rabbits. *International Journal for Sciences and Technology*, 143(2495), 1-13.
- Al-Jassim K.B., Jawad A.A.D.H., Al-Masoudi E.A., Majeed S.K. 2016. Histopathological and biochemical effects of ivermectin on kidney functions, lung and the ameliorative effects of vitamin c in rabbits (*Lupus cuniculus*). *Basrah J Vet Res*; 14: 110-24
- Arise R.O., Malomo S.O. 2009. Effects of ivermectin and albendazole on some liver and kidney function indices in rats. *African Journal of Biochemistry Research*, 3(5), 190-197.
- Behera S.K., Dimri U., Singh S.K., Mohanta R.K. 2011. The curative and antioxidative efficiency of ivermectin and ivermectin+ vitamin E-selenium treatment on canine *Sarcoptes scabiei* infestation. *Veterinary research communications*, 35(4), 237-244.
- Campbell C.W. 2012. History of avermectin and ivermectin, with notes on the history of other macrocyclic lactone antiparasitic agents. *Current pharmaceutical biotechnology*, 13(6), 853-865.
- Campbell W.C. 2016. Ivermectin: a reflection on simplicity (nobel lecture). *Angewandte Chemie International Edition*, 55(35), 10184-10189.
- El-Far A.H. 2013. Effect of therapeutic and double therapeutic doses of ivermectin on oxidative status and reproductive hormones in male rabbits. *American Journal of Animal and Veterinary Sciences*, 8(3), 128-133.
- ElZoghby R.R., Amin A., Hamouda A.F., Ali A.F. 2015. Toxicological and pathological studies of Ivermectin on male albino rats. *J. Am.Sci.* 11(3):73- 83.
- Guzzo C.A., Furtak C.I., Porras A.G., Chen C., Tipping R., Clineschmidt C.M., ... Lasseter K.C. 2002. Safety, tolerability, and pharmacokinetics of escalating high doses of ivermectin in healthy adult subjects. *The Journal of Clinical Pharmacology*, 42(10), 1122-1133.
- Khaldoun Oularbi H., Richeval C., Lebailly N., Zerrouki-Daoudi N., Baha M., Djennas N., Allorge, D. 2017. Ameliorative effect of vitamin C against hepatotoxicity induced by emamectin benzoate in rats. *Human & experimental toxicology*, 36(7), 709-717.
- Khaldoun-Oularbi H., Allorge D., Richeval C., Lhermitte M., Djenas N. 2015. Emamectin benzoate (Proclaim®) mediates biochemical changes and histopathological damage in the kidney of male Wistar rats (*Rattus norvegicus*). *Toxicologie Analytique et Clinique*, 27(2), 72-80.
- Li M., You T.Z., Zhu W. J., Qu J. P., Liu C., Zhao B., ... Li S. 2013. Antioxidant response and histopathological changes in brain tissue of pigeon exposed to avermectin. *Ecotoxicology*, 22(8), 1241-1254.
- Lu M., Xiong D., Sun W., Yu T., Hu Z., Ding J., Pan B. 2017. Sustained release ivermectin-loaded solid lipid dispersion for subcutaneous delivery: in vitro and in vivo evaluation. *Drug delivery*, 24(1), 622-631.
- Mandl J., Szarka A., Banhegyi G. 2009. Vitamin C: update on physiology and pharmacology. *British journal of pharmacology*, 157(7), 1097-1110.
- Omondi E.O., Nyabadza F., Bonyah E., Badu K. 2017. Modeling the infection dynamics of onchocerciasis and its treatment. *Journal of Biological Systems*, 25(02), 247-277.
- Omshi F.S.H., Abbasalipourkabir R., Abbasalipourkabir M., Nabyan S., Bashiri A., Ghafourikhosroshahi A. 2018. Effect of vitamin A and vitamin C on attenuation of ivermectin-induced toxicity in male Wistar rats. *Environmental Science and Pollution Research*, 25(29), 29408-29417.
- Singh R., Verma P. K., Singh G. 2012. Total phenolic, flavonoids and tannin contents in different extracts of *Artemisia absinthium*. *Journal of Complementary Medicine Research*, 1(2), 101-104.





# BENEFICIAL EFFECTS OF ASCORBIC ACID AGAINST NEPHROTOXICITY INDUCED BY IVERMECTIN REPEATED HIGH-DOSE THERAPY IN RABBITS (*ORYCTOLAGUS CUNICULUS*)

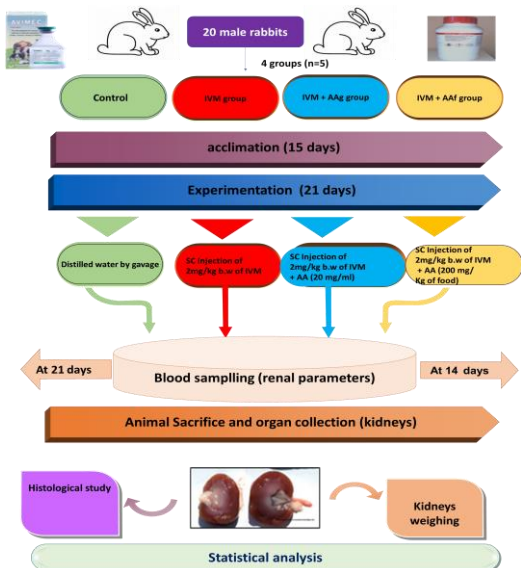


Makhlouf C.\*, Khaldoun Oularbi H., Zerrouk N.H., Bokreta S., Oularbi Y., Tlili T., Aroun R., Zerrouki Daoudi N.  
Email: \* chahrazedmakhlouf@yahoo.com

## 1. Context and objectives:

Ivermectin (IVM) is a lipophilic anthelmintic drugs widely used for the control of internal and external parasites in both human and veterinary medicine. The present experiment pertains to the protective role of ascorbic acid (AA) against biochemical and histopathological nephrotoxicity induced by IVM repeated high dose therapy in male young rabbits (*Oryctolagus cuniculus*).

## 2. Materials and methods



## 3. Results :

Table 1: Effects of IVM and IVM + AA treatments on body weight (BW), body weight gain (BWG) (%) and absolute and relative kidney weights in rabbits, 21 days after treatment

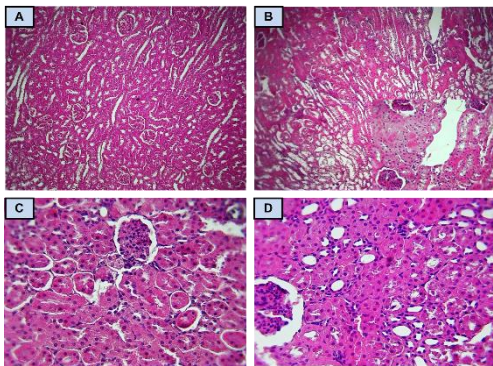
Period / Groups			Control	IVM	IVM + AAg	IVM + AAF
experimentation	Initial BW (g)		1347.1±21.1	1329.6±19.8	1351.0 ±26.6	1326.3±36.4
	Final BW (g)		1806.4±63.2	1586.0±71.6*	1693.0 ±47.1*	1676.1±1.0*
	% BWG		34.10±0.47	19.28±0.8*	25.31 ± 0.77 *	26.3 ±0.82 *
	RK weight (g)	absolute	5.7±0.9	6.8±1.3 *	6.1 ± 0.7	6.2 ± 0.8
		relative	0.3±0.0	0.4±0.1 *	0.3 ± 0.0	0.3 ± 0.1
	LK weight (g)	absolute	6.0±0.7	6.7±1.4 *	6.3 ±0.7	6.3 ± 1.8
		relative	0.3±0.0	0.4±0.1 *	0.4 ± 0.0	0.4 ± 0.1

Table 2: Effects of treatments on plasma levels of kidney biochemical markers in rabbits from control, IVM and IVM + AA-treated groups (IVM + AA, IVM + AAF)

Period	Blood chemistry parameters	Experimental groups			
		Control	IVM	IVM + AA	IVM + AAF
14 days	Creatinine (mg/dl)	7.17±0.02	10.9±0.01*	7.5±0.37	8.85±0.14*
	Urea (mg/dl)	0.27±0.0	0.32±0.0	0.24±0.01	0.29±0.01
	Uric acid (mg/dl)	4.6±0.0	5.1±0.0	5.0±0.6	4.9±0.4
21 days	Creatinine (mg/dl)	7.24±1.69	8.58±0.88*	7.38±0.51	7.72±1.3
	Urea (mg/dl)	0.27±0.01	0.34±0.02	0.25±0.02	0.30±0.03
	Uric acid (mg/dl)	4.6±0.0	5.2±0.0	4.6±1.4	4.7±0.3

IVM: Ivermectin; AA: Ascorbic Acid; AAG: Ascorbic Acid by gavage; AAF: Ascorbic Acid supplemented in food  
RK: right kidney; LK: left kidney  
Results are given as a mean ± SD for five rabbits in each group.  
IVM and AA co-treated groups vs. control group: \* p < 0.05.

Figure 1: Histology of the renal parenchyma of control (A), IVM (B), IVM+AAg (C) and IVM+AAF (D) treated rabbits (haematoxylin and eosin, X 400)



## 4. Conclusion :

The findings presented from this study have revealed that ivermectin repeated high-dose therapy in rabbits may cause impairment of the renal biochemical and histological parameters and that ascorbic acid co-treatment could reduce the degree of ivermectin toxicity. Careful application should be considered when using ivermectin on wide scale in rabbits and others farm animals.