



PROCEEDINGS OF THE 12th WORLD RABBIT CONGRESS

Nantes (France) - November 3-5, 2021

ISSN 2308-1910

Session **PATHOLOGY & HYGIENE**

Bokreta S., Khaldoun H., Makhoulf C., Daoudi-Zerrouki N.

THE POSSIBLE ALLEVIATING EFFECT OF *THYMUS VULGARIS* ESSENTIAL OIL
AGAINST VOLIAM TARGO® INDUCED CARDIOTOXICITY
IN RABBITS OF A LOCAL POPULATION (*ORYCTOLAGUS CUNICULUS*)

Full text of the communication

+

Slides of the oral presentation

How to cite this paper

Bokreta S., Khaldoun H., Makhoulf C., Daoudi-Zerrouki N., 2021. The possible alleviating effect of *Thymus vulgaris* essential oil against VOLIAM TARGO® induced cardiotoxicity in rabbits of a local population (*Oryctolagus cuniculus*). Proceedings 12th World Rabbit Congress - November 3-5 2021 - Nantes, France, Communication P-09, 4 pp. + presentation

THE POSSIBLE ALLEVIATING EFFECT OF *THYMUS VULGARIS* ESSENTIAL OIL AGAINST VOLIAM TARGO® INDUCED CARDIOTOXICITY IN RABBITS OF A LOCAL POPULATION (*ORYCTOLAGUS CUNICULUS*)

Bokreta S.^{1,2*}, Khaldoun H.^{1,2}, Makhlouf C.¹, Daoudi-Zerrouki N.²

¹Departement of Biology, Faculty of Nature and Life Science, University Blida 1, BP 270- Soumaa- Blida- Algeria

²Natural Resources Laboratory, University Mouloud Mammeri, BP 15017. Tizi-Ouzou. Algeria

*Correspondance Bokreta Soumya: e-mail: bokretasoumya@gmail.com

ABSTRACT

The aim of the present study is to evaluate the potential cardiotoxicity of Voliam Targo® (VT) and to investigate the protective effect of a co-administration of the *Thymus vulgaris* essential oil against heart histopathological alterations in male rabbits. Twenty adult rabbits were divided into four equal groups and treated for 21 consecutive days: control, voliam targo® (VT), thyme essential oil (TEO) and voliam targo® plus thyme essential oil (VT+TEO) groups. Subacute exposure to VT caused a significant decrease in mean body weight compared to control. Absolute and relative heart weights were significantly altered in VT group. This study revealed no changes in coronary risk index (TC/HDLc) level, while, atherogenic index of plasma and LDL-C/HDL-C ratio were found significantly reduced in VT-treated group compared to the other groups. The treatment with voliam targo® caused histopathological alterations in the myocardium such as congested blood capillaries, inflammatory cell infiltration, increased masses of collagen fibers around the congested blood vessels. While the co-administration of *Thymus vulgaris* essential oil showed significant improvement in morphological changes of the heart. In conclusion, exposure to VT induces toxic effect on heart tissue and the essential oil of *T. vulgaris* alleviates this deleterious effect and may have healing and protective effects.

Key words: Voliam Targo 063SCe, *Thymus vulgaris*, Essential Oil, Cardiotoxicity, Rabbit.

INTRODUCTION

Pesticides extensive use is currently one of the major and global health problem (Alarcan et al., 2020). Scientifically, exposure to pesticides has been correlated with the appearance of several human pathologies including cardiovascular diseases (Georgiadis et al., 2018). "Voliam Targo 063SCe" (VT) is a new commercial formulation of abamectin-based insecticide. This biocide contains two active ingredients, abamectin and chlorantraniliprole belonging to two different families, the bisamide and the avermectin. It is effective on several key pests of fruits and vegetables. So far, many studies have revealed that pesticides have adverse effects in heart tissue (Thomaz et al., 2009; Baş and Kalender, 2011, Ahmed et al., 2016). However, to date, information on histopathological changes induced by exposure to abamectin-based insecticides in the heart is rare. Nowadays, a growing interest has been noted on the significance of natural resources that can be consumed in an individual's everyday diet. Among these, *Thymus vulgaris* L is an herbaceous, perennial aromatic plant, belonging to the Lamiaceae family and indigenous in the Mediterranean region (Ghavam, 2018). It is widely utilized in folk medicine due to its antimicrobial, anti-inflammatory and antioxidant potentials (Taghouti et al., 2020). It has been postulated that a fraction of these properties is related to its essential oil (Fachini-Queiroz et al., 2012). Within this context, the present study aimed to evaluate the effects of Voliam Targo® on histological changes of cardiac tissue and to investigate the possible protective role of *T. vulgaris* essential oil in male rabbit of (*Oryctolagus cuniculus*).

MATERIALS AND METHODS

Chemicals

The molecule tested "Voliam Targo®063SCe" in the present study is a commercial formulation of an insecticide composed of two active ingredients: chlorantraniliprole 4,5% and abamectin, 1,8%

marketed by SYNGENTA Crop Protection Agrochemicals, Greensboro, USA. All other chemicals and biochemical reagents used in the current study were purchased from commercial sources (BIOLABO SA, France).

Animals and experimental procedure

Healthy adult male rabbits (*Oryctolagus cuniculus*, 2.5 ± 0.1 kg) were used in this experiment and divided into 4 groups (5 rabbits each). The rabbits were provided by the Technical Breeding Institute (ITELV, Baba-Ali) and kept for experimentation in the CRD Saidal Algeria. They were acclimatized for 3 weeks prior to the experiment in standard cages at 25 ± 3 °C under a 12 h/12 h light/dark cycle. The rabbits received a standard commercial diet and water *ad libitum*.

Animals were randomly divided into four experimental groups as follows: Group 1 (C): control group. Group 2 (VT): rabbits were orally intoxicated with VT pesticide at a dose that containing 4mg/kg abamectin and 11 mg /kg chlorantraniliprole daily for 21 days. Group 3 (TEO): rabbits were treated with thyme essential oil alone at a concentration of 0.5 mg/kg per day for 21 days. Group 4 (VT + TEO): rabbits received 0.5 mg/kg b.w of *Thymus vulgaris* essential oil plus the same dose of VT as in VT-treated group. At the end of the experimental period, rabbits were sacrificed and heart tissues were collected for histopathological analysis.

Biochemical analysis

To better assess the cardiotoxicity of VT, some atherogenic indices were determined, namely atherogenic index of plasma (AIP), atherogenic index (LDL-C/HDL-C ratio) and coronary risk index (TC/HDL-C ratio). The atherogenic index of plasma (AIP) was calculated as $\text{Log}_{10} [\text{TGs}] / [\text{HDL-C}]$ according to Króliczewska et al. (2018).

Histological examination

The specimens of the heart were isolated and immediately fixed in 10% neutral formalin saline. Dehydration was then carried out in ascending series of ethyl alcohol followed by clearing with xylene. The tissues were then embedded in paraffin wax and serial sections of 5 µm thickness were obtained with Leica rotatory microtome. The sections were then stained with haematoxylin-eosin stain and Masson's trichrome stain and examined under light microscope.

Statistical Analysis

Data were presented as means \pm the standard error of means. Statistical analyses were performed using Statistica version 10.0 (Stat Soft Inc., Tulsa, Oklahoma, USA) and one-way ANOVA. Duncan's multiple-range test was used to determine differences among groups with significance set at $P < 0.05$.

RESULTS AND DISCUSSION

Effects of treatments on heart and body weights

No deaths were observed in any of the experimental groups. There was a homogeneous weight gain in the control rabbits, those treated with TEO and those treated with VT + TEO. However, VT treatment resulted in a significant decrease ($p < 0.05$) in the average body weight and body weight gain. Similarly, absolute and relative heart weights were significantly reduced in VT treated group (Table 1). The decrease in body weight of rabbits treated with VT may be attributed to lower intake of food and drink due to treatment-related toxicity (Mansour and Mossa, 2010). Our results agreed with our previous studies in rats, showing that exposure to avermectin insecticide (abamectin or Enamectin benzoate) significantly reduced body weight gain (Khaldoun Oularbi *et al.*, 2013 ; Khaldoun Oularbi *et al.*, 2015).

Table 1: Effect of Voliam targo® and/or TEO treatment on body weight, absolute and relative heart weights

Groups	Control	VT	TEO	VT + TEO
Initial BW (kg)	2.81 ± 0.01 ^a	2.79 ± 0.06 ^a	2.86 ± 0.02 ^a	2.92 ± 0.04 ^a
Final BW (kg)	3.14 ± 0.03 ^a	2.94 ± 0.07^b	3.17 ± 0.02 ^a	3.20 ± 0.05 ^a
% BWG	11.7	5.4	10.8	9.6
Absolute heart weight (g)	7.67 ± 0.02 ^a	6.84 ± 0.22^b	6.95 ± 0.32 ^a	7.39 ± 0.27 ^a
Relative heart weight	0.25 ± 0.00 ^a	0.22 ± 0.00^b	0.24 ± 0.03 ^a	0.25 ± 0.01 ^a

Data are represented as Mean ± SD (n=05). Means within the same row, which do not share the same superscript symbol(s), are significantly different at p < 0.05. AIP: Atherogenic Index of Plasma, VT Voliam Targo®, TEO *Thymus vulgaris* essential oil
. BWG: Body weight gain.

Effects of treatments on atherogenic indices

In comparison with control data, the atherogenic index (LDL-C/HDL-C) and the AIP levels of rabbits treated with VT were statistically decreased (Table 2). This is probably related to the plasma elimination of Voliam targo® in the treated rabbits, which is supported by Khaldoun et al. (2015) who have demonstrated that avermectins can be simply eliminated from the plasma

after cessation of treatment whereas their accumulation occurs in other biological matrices or organs due to its lipophilicity which is at the origin of their toxicity. Avermectins xenobiotics are very hydrophobic molecules which are distributed in plasma via the LDLc, HDLc and VLDL plasma lipoprotein particles. Thus, the pharmacokinetic of avermectins is influenced by plasma lipoprotein levels (Bassissi et al., 2004).

Table 2: Effect of Voliam targo® and/or TEO treatment on atherogenic indices

Groups	Control	VT	TEO	VT + TEO
AIP	0.53 ± 0.07 ^a	0.25 ± 0.02^b	0.60 ± 0.09 ^a	0.42 ± 0.06 ^a
LDL-C/HDL-C	1.54 ± 0.09 ^a	0.75 ± 0.05^b	0.73 ± 0.05 ^b	1.04 ± 0.05 ^a
TC/HDLc	3.27 ± 0.07 ^a	2.19 ± 0.08 ^a	2.47 ± 0.04 ^a	2.35 ± 0.03 ^a

Data are represented as Mean ± SD (n=05). Means within the same row, which do not share the same superscript symbol(s), are significantly different at p < 0.05. AIP: Atherogenic Index of Plasma, VT Voliam Targo®, TEO *Thymus vulgaris* essential oil

Effects of treatments on heart histological structure

Histomicrographs of hematoxylin and eosin (H&E) and Masson's trichrome stained sections of the heart specimen from different treatment groups are shown in Figure 1. The cardiac sections of the control and TEO-treated

rabbits showed the same normal histoarchitecture of cardiac tissue, which was formed of normal typical cardiac muscle fibers with several small blood vessels and myofibrillar structure with striations. The five rabbits treated with VT alone displayed the same histopathological changes of cardiac tissue, namely congested blood capillaries, inflammatory cell infiltration, increased masses of collagen fibers among the cardiac muscle fibers and around the congested blood vessels Focal parts of extensive collagen fiber deposition were also noticed. While the co-administration of *Thymus vulgaris* essential oil showed significant improvement in morphological alterations of the heart. Thus, this essential oil may play a protective role against VT mediated cardiotoxicity through its antioxidant and free radical scavenging properties.

CONCLUSIONS

In conclusion, the findings of this study indicate that sub-acute exposure to Voliam targo® may induce toxic effect to cardiac tissues. This deleterious effect could be ameliorated by *T. vulgaris* essential oil which has healing and protective properties probably through its antioxidant potential and free radical-scavenging activity.

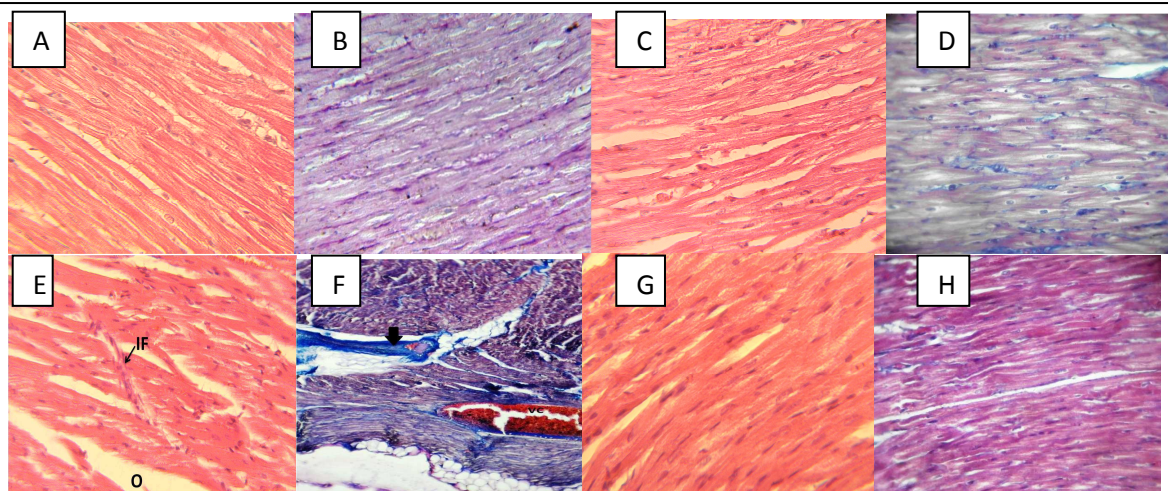


Figure 1: Photomicrographs of rabbit heart sections stained with H&E and Masson's trichrome. Sections of control (A and B) and TEO (C and D) treated rabbits showing normal cardiac histoarchitecture. Section of rabbits treated with VT (E and F) showing vascular congestion (VC), extensive amounts of collagen fibers among the cardiac muscle fibers and around the congested dilated blood vessels (bleu color) and cell infiltration (IF). Cardiac sections from VT+TEO treated rabbits (G and H) showing few collagen fibers with a nearly normal histologic pattern. (X100, X400).

REFERENCES

- Alarcan J., Waizenegger J., Solano M. d. L. M., Lichtenstein D., Luckert C., Peijnenburg N. et al. 2020. Hepatotoxicity of the pesticides imazalil, thiacloprid and clothianidin–Individual and mixture effects in a 28-day study in female Wistar rats. *Food and Chemical Toxicology.*, 111306.
- Georgiadis N., Tsarouhas K., Tsitsimpikou C., Vardavas A., Rezaee R., Germanakis I., et al. 2018. Pesticides and cardiotoxicity. Where do we stand? *Toxicology and applied pharmacology.*, 353, 1-14.
- Khaldoun Oularbi H., Zerrouki N., Richeval C., Aissani H., Elemdani M. R., Djennas N. 2013. Vertimec® mediates plasma biochemical changes and histopathological damage in the kidney of rats (*Rattus norvegicus*). *Agriculture & Food.*, 5, 622-630.
- Thomaz J. M., Martins N. D., Monteiro D. A., Rantin F. T., & Kalinin A. L. 2009. Cardio-respiratory function and oxidative stress biomarkers in Nile tilapia exposed to the organophosphate insecticide trichlorfon (NEGUVON®). *Ecotoxicology and environmental safety.*, 72(5), 1413-1424.
- Bas H., & Kalender Y. 2011. Chlorpyrifos induced cardiotoxicity in rats and the protective role of quercetin and catechin. *Gazi University Journal of Science.*, 24(3), 387-395.
- Ahmed O. M., Fahim H. I., Boules M. W., & Ahmed H. Y. 2016. Cardiac and testicular toxicity effects of the latex and ethanolic leaf extract of *Calotropis procera* on male albino rats in comparison to abamectin. *SpringerPlus.*, 5(1), 1644.
- Ghavam M. 2018. Effect of silver nanoparticles on seed germination and seedling growth in *Thymus vulgaris* L. and *Thymus daenensis* Celak under salinity stress. *Journal of Rangeland Science.*, 8(1), 93-100.
- Taghouti M., Martins-Gomes C., Félix L. M., Schäfer J., Santos J. A., Bunzel M., et al. 2020. Polyphenol composition and biological activity of *Thymus citriodorus* and *Thymus vulgaris*: Comparison with endemic Iberian *Thymus* species. *Food Chemistry.*, 331, 127362.
- Fachini-Queiroz F. C., Kummer R., Estevao-Silva C. F., Carvalho M. D. d. B., Cunha J. M., Grespan R., et al. 2012. Effects of thymol and carvacrol, constituents of *Thymus vulgaris* L. essential oil, on the inflammatory response. *Evidence-Based Complementary and Alternative Medicine*, 2012.
- Króliczewska B., Miśta D., Ziarnik A., Żuk M., Szopa J., Pecka-Kielb .E, et al. 2018. The effects of seed from *Linum usitatissimum* cultivar with increased phenylpropanoid compounds and hydrolysable tannin in a high cholesterol-fed rabbit. *Lipids in health and disease.*, 17(1), 76.
- Mansour S. A., & Mossa A.T. H. 2010. Oxidative damage, biochemical and histopathological alterations in rats exposed to chlorpyrifos and the antioxidant role of zinc. *Pesticide Biochemistry and Physiology.*, 96(1), 14-23.
- Khaldoun Oularbi H., Allorge D., Richeval C. 2015. Emamectin benzoate (Proclaim®) mediates biochemical changes and histopathological damage in the kidney of male Wistar rats (*Rattus norvegicus*). *Toxicol Anal Clin.*, 27, 72–80.
- Bassissi M. F., Alvinerie M., & Lespine A. 2004. Macrocyclic lactones: distribution in plasma lipoproteins of several animal species including humans. *Comparative Biochemistry and Physiology Part C: Toxicology & Pharmacology.*, 138(4), 437-444.



12th World Rabbit Congress

November 3-5 2021 – Nantes, France



University of Mouloud Mammeri Tizi-Ozou

Faculty of Biological Sciences

**Natural Resources Laboratory, University Mouloud Mammeri, BP 15017. Tizi-Ouzou,
Algeria**

THE POSSIBLE ALLEVIATING EFFECT OF THYMUS VULGARIS ESSENTIAL OIL AGAINST VOLIAM TARGO® INDUCED CARDIOTOXICITY IN RABBITS OF A LOCAL POPULATION (ORYCTOLAGUS CUNICULUS)

Prepared By

Mme. BOKRETA Soumya

Co-Authors: Khaldoun H., Makhlouf C., Daoudi-Zerrouki N.



November 4, 2021

Pesticide

Synonyme
de maladie,
de ravage

Synonyme
de tuer



Les HERBICIDES



destinés à tuer
les herbes

Les INSECTICIDES



destinés à tuer
les insectes

Les FONGICIDES

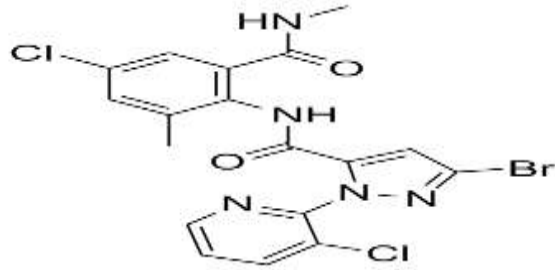


destinés à lutter contre
les maladies des plantes
dûes aux champignons

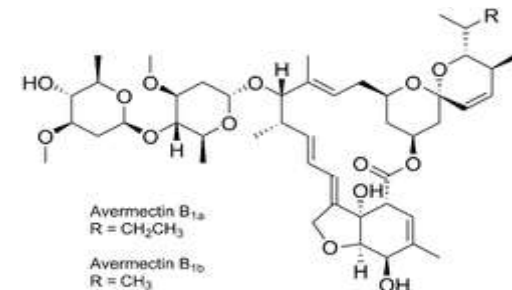
Les SOURICIDES, RATICIDES, NÉMATOCIDES



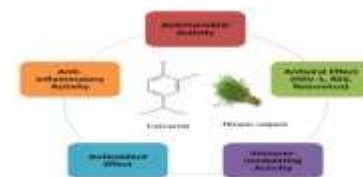destinés à se débarrasser
de divers animaux jugés
nuisibles (vers, limaces, rats ...)



Introduction



- Pesticides use is a major burden of disease **worldwide**.
- **Evidence** continues to **accumulate** that **pesticide exposure** is associated with the appearance of **CVD**.
- **Voilam Targo® (VT)** is an insecticide composed of two active ingredients **abamectin** and **chlorantraniliprole**, belonging to two different chemical families.
- Recently, there has been a **growing interest** in using **natural resources**.
- *Thymus vulgaris L.* (Lamiaceae family), medicinal plant with **various therapeutic properties**.



Objectives



- To evaluate the cardiotoxic effect of Voliam targo® (VT) on biochemical and histological parameters;



- To investigate the possible protective effect of *Thymus vulgaris* essential oil (TEO) supplementation against the experimental toxicity of VT in male rabbit (*Oryctolagus cuniculus*).

MATERIALS AND METHODS

Experimental procedure

20 male rabbits
(*Oryctolagus
cuniculus*)



Gr 1

Control

Gr 2

**Treated
with TEO**

Gr 3

**Traited
with
VT**

Gr 4

**Traited
with
VT + TEO**



Treatments were given daily, by oral gavage for 21 consecutif days.

RESULTS AND DISCUSSION

■ Effects of treatments on heart and body weights

VT treatment resulted in a significant decrease ($p < 0.05$) in the body weight gain, absolute and relative heart weights in treated rabbits compared to control.

Table 1: Effect of treatments on body weight, absolute and relative heart weights

Groups	Control	TEO	VT	VT + TEO
Initial BW (kg)	2.81 ± 0.01^a	2.86 ± 0.02^a	2.79 ± 0.06^a	2.92 ± 0.04^a
Final BW (kg)	3.14 ± 0.03^a	3.17 ± 0.02^a	2.94 ± 0.07^b	3.20 ± 0.05^a
% BWG	11.7	10.8	5.4	9.6
Absolute heart weight (g)	7.67 ± 0.02^a	6.95 ± 0.32^a	6.84 ± 0.22^b	7.39 ± 0.27^a
Relative heart weight	0.25 ± 0.00^a	0.24 ± 0.03^a	0.22 ± 0.00^b	0.25 ± 0.01^a

Data are represented as Mean \pm SD (n=05). Means within the same row, which do not share the same superscript symbol(s), are significantly different at $p < 0.05$. BWG: Body weight gain.

- **Effect of treatments on atherogenic indices**

In comparison with control data, the atherogenic index (LDL-C/HDL-C) of rabbits treated with VT were statistically decreased.

Table 2: Effect of treatments on atherogenic indices

Groups	Control	TEO	VT	VT + TEO
AIP	0.53 ± 0.07 ^a	0.25 ± 0.02^b	0.60 ± 0.09 ^a	0.42 ± 0.06 ^a
LDL-C/HDL-C	1.54 ± 0.09 ^a	0.75 ± 0.05^b	0.73 ± 0.05^b	1.04 ± 0.05 ^a
TC/HDLc	3.27 ± 0.07 ^a	2.19 ± 0.08 ^a	2.47 ± 0.04 ^a	2.35 ± 0.03 ^a

Data are represented as Mean ± SD (n=05). Means within the same row, which do not share the same superscript symbol(s), are significantly different at $p < 0.05$. *AIP*: Atherogenic Index of Plasma, *VT* Voliam Targo®, *TEO* *Thymys vulgaris* essential oil

HISTOLOGICAL RESULTS

- Effects of treatments on heart histological structure

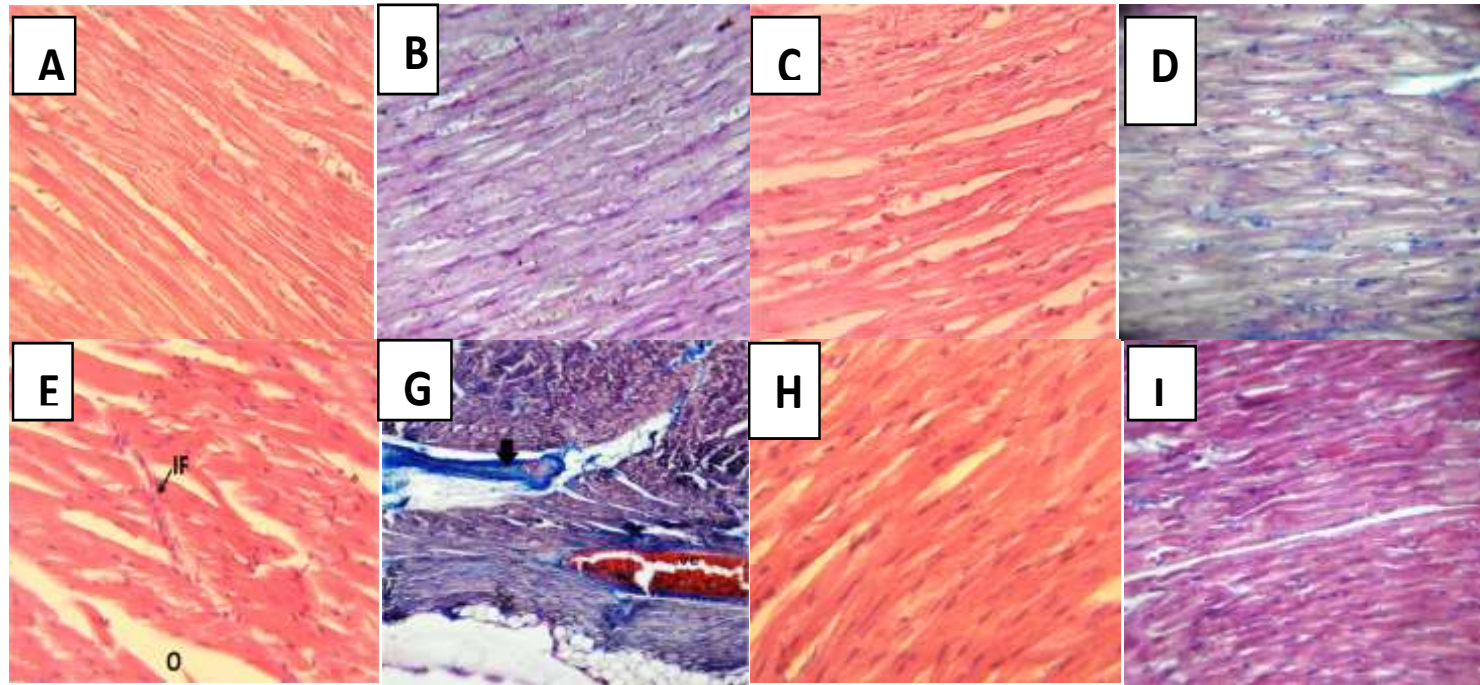


Figure 1: Photomicrographs of rabbit heart sections stained with H&E and Masson's trichrome. Sections of control (A and B) and TEO (C and D) treated rabbits showing normal cardiac histoarchitecture. Section of rabbits treated with VT (E and F) showing vascular congestion (VC), extensive amounts of collagen fibers among the cardiac muscle fibers and around the congested dilated blood vessels (bleu color) and cell infiltration (IF). Cardiac sections from VT+TEO treated rabbits (G and H) showing few collagen fibers with a nearly normal histologic pattern. (X100, X400).

CONCLUSION

- The findings of this study indicate that sub-acute exposure to Voliam targo[®] may induce toxic effect to cardiac tissues.
- This deleterious effect could be ameliorated by *T. vulgaris* essential oil which has healing and protective properties probably *through* its antioxidant potential and free radical-scavenging activity.

