



PROCEEDINGS OF THE 12th WORLD RABBIT CONGRESS

Nantes (France) - November 3-5, 2021

ISSN 2308-1910

Session ETHOLOGY & WELFARE

Rommers J., de Greef K.

**ARE PLASTIC MATS EFFECTIVE FOR DIMINISHING FOOTPAD LESIONS OF
RABBIT DOES? – SURVEY AFTER 10 YEARS IN THE NETHERLANDS**

Full text of the communication

+

Slides of the oral presentation

How to cite this paper

Rommers J., de Greef K., 2021. Are plastic mats effective for diminishing footpad lesions of rabbit does? – Survey after 10 years in the Netherlands. Proceedings 12th World Rabbit Congress - November 3-5 2021 - Nantes, France, Communication E-13, 4 pp. + presentation

ARE PLASTIC MATS EFFECTIVE FOR DIMINISHING FOOTPAD LESIONS OF RABBIT DOES? – SURVEY AFTER 10 YEARS IN THE NETHERLANDS

Rommers J., de Greef K.

Wageningen Livestock Research, De Elst 1, 6800 AB Wageningen, The Netherlands; email address:

Jorine.Rommers@wur.nl

ABSTRACT

At four farms in The Netherlands (10% of all farms), footpad injuries were scored to evaluate whether a plastic mat attached to the wire mesh floor is effective in diminishing serious footpad lesions in rabbit does, 10 years after the plastic mat was made mandatory in rabbit does cages in The Netherlands. Footpad injuries were scored once (scoring 0-3) in 100 does at each farm. Parity and footpad score were registered. The number of young does (≤ 2 litters) was limited to 25% per farm, as footpad injuries are mostly seen in older does. Farms were quite comparable in footpad scores, the average footpad score ranged from 0.8 to 1.1. On average 43% of the does had intact footpads, 55% had a callus and 2.5% had cracks in the callus, no wounds were observed. Based on the results, rabbit does housed in the wire floor cages furnished with plastic mats show no serious injuries to the footpads. The earlier expectation and the ambition of the regulation that the plastic mat prevents pododermatitis is clearly met.

Keywords: rabbit does, welfare, housing, cage housing

INTRODUCTION

Pododermatitis in the rabbit is an often occurring illness of varying severity of the sole of the hindlimb (Drescher and Schlender-Böbbis, 1996). Signs of the condition begin with a small alopecic area on the ventral surface of the foot; this lesion then becomes erythematous and often evolves into an ulcer (Olivas et al., 2013). This is known as ‘sore hocks’. Later, if left untreated, the lesion can become infected with bacteria and fungi. The infection can spread into the blood, resulting in sepsis, or to the bone, causing osteomyelitis (Martorell, 2014). The disease is assumed to be progressive, whereby initially scaly, hairless regions with thickened skin eventually ulcerate at a later stage (Ruchti *et al.*, 2018). In farm conditions, it is commonly seen in older rabbit does (≥ 3 parities) housed on a wire mesh floor (Rommers and Meijerhof, 1996; EFSA, 2005; Rommers and de Jong, 2011; Rosell and de la Fuente, 2013). Pododermatitis compromises the welfare of the animals (Drescher and Schlender-Böbbis, 1996; EFSA, 2005). It can cause chronic suffering, especially if the lesions are severe (EFSA, 2005, de Jong *et al.*, 2008, Ruchti *et al.*, 2018). Recently, EFSA (2020) categorized ulcerations due to pododermatitis as a relevant welfare consequence. Footpad injuries not only comprise welfare, but also affect productivity (Rosell and de la Fuente, 2009) and are an important reason for culling (EFSA, 2005, Rosell and de la Fuente, 2009). Therefore, it is also of economic importance.

In the nineties of the last century in the Netherlands, footpad injuries in rabbit does were depicted as relevant and research was started into the effect of alternative floors (other than wire mesh) on the occurrence of footpad injuries. It emerged that footpad injuries in rabbit does diminished on certain alternative floors. However, rabbits gnawed on the plastic floors and the floors were highly contaminated. A good alternative to the wire mesh floor was not available at that time (Rommers and Meijerhof, 1996). Around 2007, a plastic mat that could be mounted on the wire mesh floor was introduced in commercial farms in the Netherlands (see Figure 1). According to farmers, this mat

seemed to minimize footpad injuries. Therefore, an experiment was carried out in 2008 on five commercial farms by the Wageningen Livestock Research (The Netherlands) (Rommers and De Jong, 2011). It turned out that with the plastic mat on the wire mesh floor, footpad injuries declined compared to the wire mesh floor. After five parities, 13.3% of rabbit does housed on wire floor had intact footpads, whereas on the plastic mat this percentage was 81.3%. The average footpad score (scale 0 to 4) was also significantly lower on the plastic mat (0.17 compared to 0.32 for plastic mat and the wire floor, respectively). The effect of the plastic mat was mainly effective in older does (>3 parities). In particular, intact footpads or footpads with a callus area smaller than 2.5 cm in diameter were found on the plastic mat, while footpads with cracks and wounds were found on the wire mesh floor (Rommers and de Jong, 2011). Because of the beneficial effect of plastic mats in reduction of pododermatitis, the plastic mat (or other material with similar properties to plastic) with a minimum of 900 cm², was made mandatory for rabbit does and included in 2009 to the by farmers self-imposed regulation from 2006 ("Welzijnsverordening konijnen"; PPE, 2006) and later incorporated in the Dutch law ("Wet Dieren") in the Netherlands. Because of the major impact of pododermatitis on the welfare of rabbit does, measures were also taken by several other countries. Belgium, Germany and Switzerland have introduced legislation which makes alternative plastic floors mandatory for rabbit does as well as for meat rabbits.

The question arises whether plastic mats, 10 years after implementation in the Netherlands, are indeed effective in practice to diminish footpad lesions. The objective of our study therefore was to make an inventory to assess whether does housed on plastic mats have reduced incidence of footpad injuries compared to a decade earlier.

MATERIAL AND METHODS

Four commercial rabbit farms were visited during winter 2018-2019, representing 10% of rabbit farms in The Netherlands. The number of does per farm ranged between 750 to 1900 does. Hyla (Hypharm, France) and Hycote rabbits (Hycote, France) were used at the farms on which different semen of different types of bucks (Hycote (Hycote, France), Hyla and Grimaud (Hypharm, France)) was used for the production of meat rabbits. Does were housed in enriched cages (Meneghin, Italy) with a wire mesh floor and a plastic mat attached to the wire mesh floor (see Figure 1). The plastic mat was 24 x 40 cm in size. Per farm 100 randomly chosen rabbit does were scored for footpad injuries. To prevent that mainly young does would be scored, a maximum of 25 young does (≤ 2 parities) were taken per farm. The others were multiparous (≥ 3 parities) rabbit does. Parity of the does was registered. The conditions of the footpads were scored as follow: 0= intact footpads; 1= no hairs, callus formed; 2= callus, cracks have formed; 3= wounds (Rommers and de Jong, 2011). The footpad score for a doe was determined by the highest score of the two footpads of the hind legs.



Figure 1. Left side: Enriched cage with plastic mat attached to the wire mesh floor (highlighted by the circle in the picture) and right side: detailed picture of the plastic mat.

RESULTS AND DISCUSSION

Figure 2 presents the distribution of the parities of the does scored for footpad injuries over the four farms. The number of does declines as parity get higher and does get older. This is a normal situation due to the regular culling and replacement of does in commercial farms. Farms were quite comparable in footpad scores, the average footpad score ranged from 0.8 to 1.1 ± 0.9 . Figure 3 shows the overall footpad scores per parity. On average 43% of the does had intact footpads, 55% had a callus and 2.5% had cracks in the callus. In two does, the score tended to an open wound while the upper skin was absent, but no blood was visible. No bloody wounds were found. Per parity the percentage of does with intact footpads declined by 3.5%, whereas the percentage of does with a callus increased by 3.6%. The percentage of does with cracks was low and increased by 0.3% per parity. This is in line with the findings of Rommers and de Jong (2011). Unexpectedly, cracks were recorded on one young doe (parity 1). Other research shows that footpad problems generally only manifest themselves around the third parity (Rommers and de Jong, 2011), the single young doe seems an exception or a registration error.

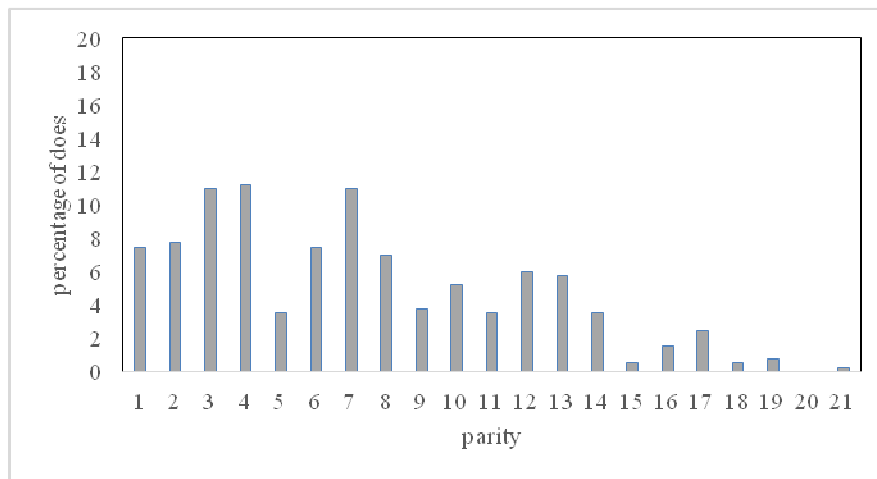


Figure 2. Distribution per parities of does used for scoring footpad injuries in four rabbit farms with 100 does samples per farm.

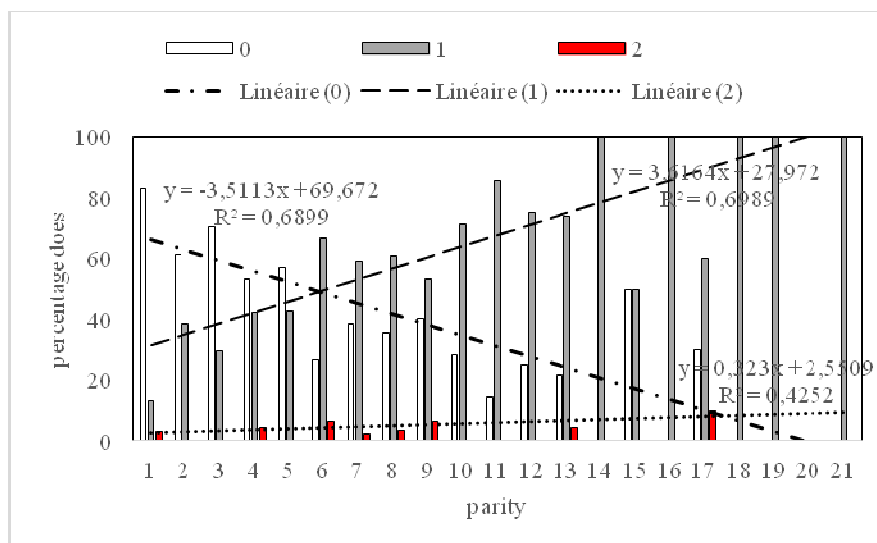


Figure 3. Footpad score according to parity with linear regression lines.

(score 0= intact, score 1= with callus, score 2= with cracks in callus, score 3= wounds

--- = linear regression line for score 0, ---- = linear regression line for score 1,= linear regression line score 2)

The purpose of this inventory was to check whether 10 years after the introduction of the plastic mat, the incidence of footpad injuries was still reduced. The results of this evaluation show that there are no severe problems with footpad injuries in rabbit does nowadays in The Netherlands thanks to the use of the plastic mat.

To what extent is the welfare of the rabbit at stake? Footpad disorders range from the baldness of the footpad through the development of calluses to real wounds. The question is at what stage the welfare of the animal is influenced. Drescher and Schlender-Böbbis (1995) stated that the welfare of rabbits was negatively influenced from the appearance of calluses, because then the damage is irreversible. We have no evidence that a callus does cause discomfort and is therefore not a deterioration of welfare. Similarly, EFSA (2020) only takes ulceration into account as discomfort. A perspective is that development of calluses is a beneficial adaptation mechanism of the animals to the pressure imposed on their soles. However, from another perspective, calluses can pose a risk (or indicate an early stadium) of fissures and wounds. Cracks and wounds can cause pain and discomfort. Despite the use of a plastic mat, in a large proportion of does develop calluses. In the current systems, cracks were found in only a small percentage of does and no wounds were observed. From a welfare point of view, the mats appear to meet expectations.

CONCLUSIONS

Rabbit does housed in the wire cage furniture with a plastic mat to protect their soles shows no injured footpads. The expectation that the plastic mats prevent pododermatitis is confirmed in practice.



REFERENCES

- Drescher B., Schlender-Böbbis I. 1996. Pododermatitis (sore hocks) in the rabbit. *Kleintierpraxis* 41, 99-103.
- European Food Safety Authority (EFSA), 2005. Scientific Report "The Impact of the current housing and husbandry systems on the health and welfare of farmed domestic rabbits". EFSA-Q-2004-023.
- European Food Safety Authority (EFSA), 2020. Health and welfare of rabbits farmed in different production systems. EFSA Journal, 18 (1): 5944. EFSA-Q-2019-00593.
- Jong de, I.C. Reimert H., Rommers J.M. 2008. Effect of floor type on footpad injuries in does: a pilot study. *9th World Rabbit Congress, June 10-13, Verona, Italy*, 1171-1175.
- Martorell J. 2014. Scoring pododermatitis in pet rabbits. *Veterinary Record*, April 26, 427-428.
- Olivas I., Torres A.G., Villagra A. 2013. Development of a pododermatitis score in breeding does using clustering methods. *Animal* 7, 6, 1011-1016.
- Dutch Product Board for Poultry and Eggs (PPE) 2006. Regulations Welfare Standard Rabbits., PPE, Zoetermeer, The Netherlands.
- Rommers J.M., Meijerhof R. 1996. The effect of different floor types on footpad injuries of rabbit does. *6th World Rabbit Congress, Toulouse 1996, Vol. 2*, 431-436.
- Rommers J.M. de Jong I.C. 2011. Technical note: Plastic mats prevent footpad injuries in rabbit does. *World Rabbit Sci.*, 19, 233 – 237. doi:10.4995/wrs.2011.868
- Rosell J.M., de la Fuente L.F. 2009. Effect of footrests on the incidence of ulcerative pododermatitis in domestic rabbit does. *Animal Welfare* 2009, 18, 199-204
- Rosell J.M., de la Fuente L.F. 2013. Assessing Ulcerative Pododermatitis of Breeding Rabbits. *Animals* 2013, 3, 318-326; doi:10.3390/ani3020318
- Ruchti S., Meier A.R., Würbel H., Kratzer G., Gebhardt-Henrich S.G., Hartnack S. 2018. Pododermatitis in group housed rabbit does in Switzerland – prevalence, severity, progression and risk factors. *Preventive Veterinary Medicine* 158, 114-121.

Are plastic mats effective for diminishing pododermatitis in rabbit does?

Survey after 10 years in the Netherlands

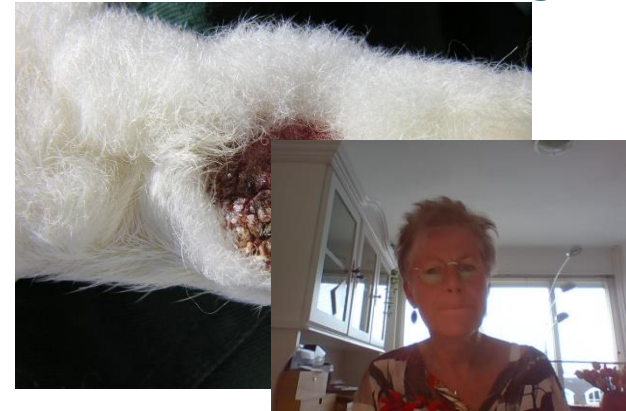
*Jorine Rommers and Karel de Greef**



Background

- Pododermatitis in rabbit does was observed as welfare problem ('90)

Pododermatitis: “hyperkeratosis and alopecia have already progressed to signs of ulceration, and in the worst cases, to crust form bloody wound secretion, deep ulceration, and degeneration of the surrounding tissues” (EFSA 2020)




Background pododermatitis

- Research into different alternative floors (1996)
 - > some alternative floors reduced pododermatitis
- Plastic mat was introduced on rabbit farms in NL around 2006
- Plastic mat declined pododermatitis in rabbit does (research 2007)
- Plastic mat mandatory in 2009 in NL

Objective

- Are plastic mat proven to be effective after 10 years in N

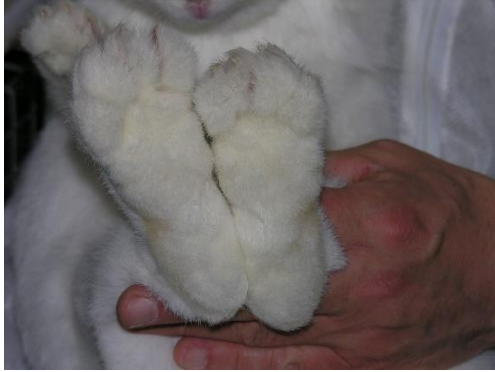

Survey at 4 rabbit farms (10% all farms NL)

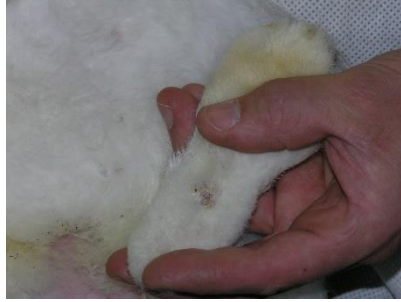Per farm:

- 100 does, randomly selected ($< 25\%$ young does)
- 2 parks meat rabbits
- Scoring according to de Jong et al (2011)

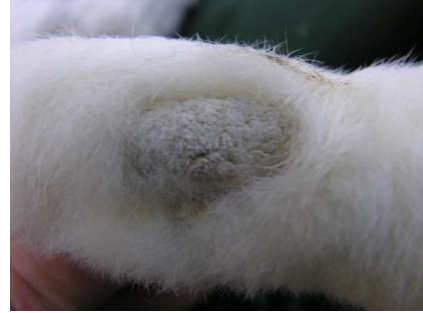



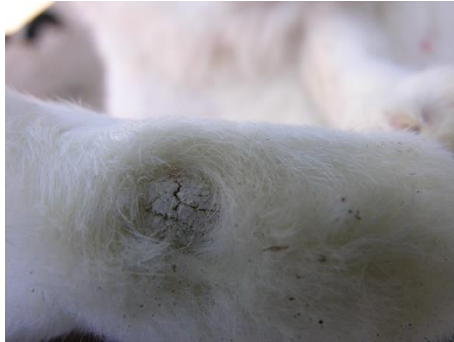Score
0



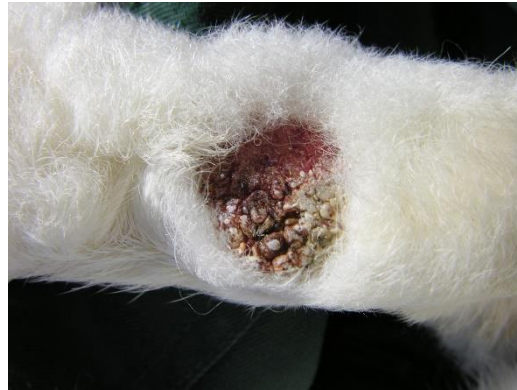Score
1



Score
1



Score
2



Score
3

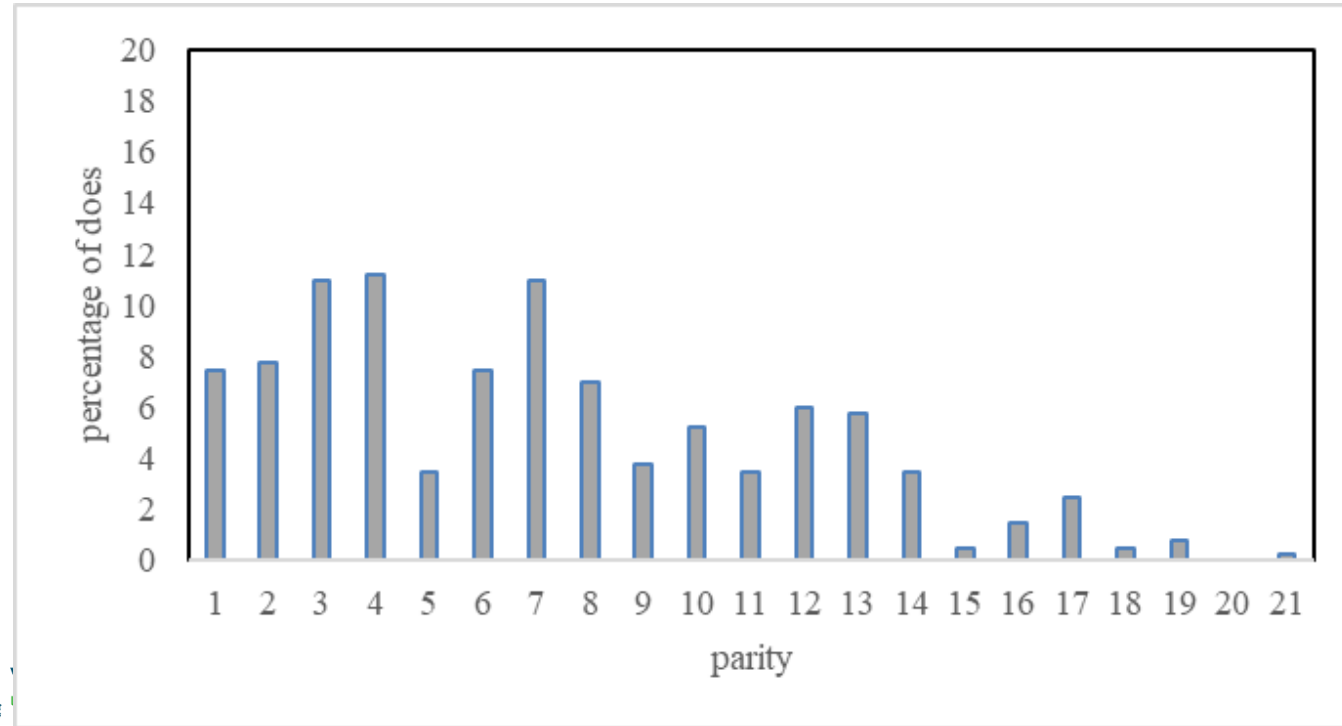


WAGENINGEN
UNIVERSITY & RESEARCH

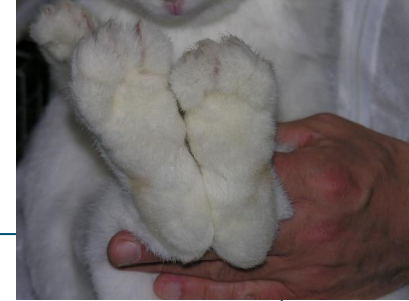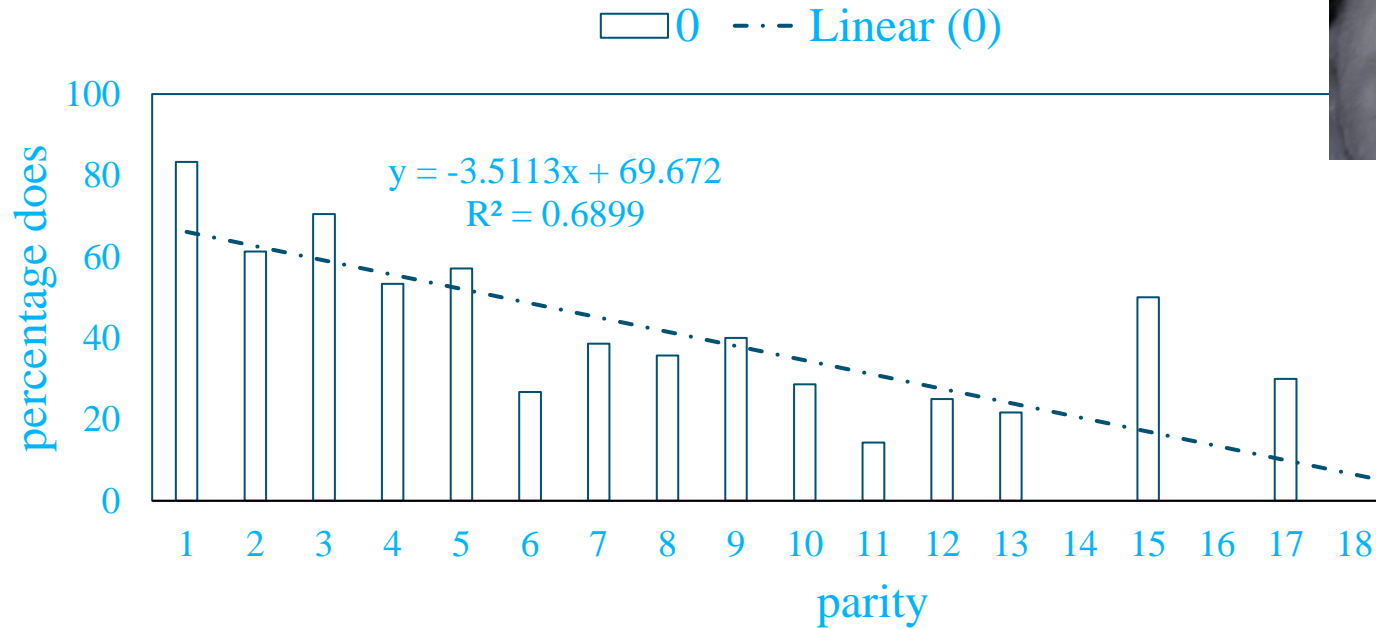


Results survey

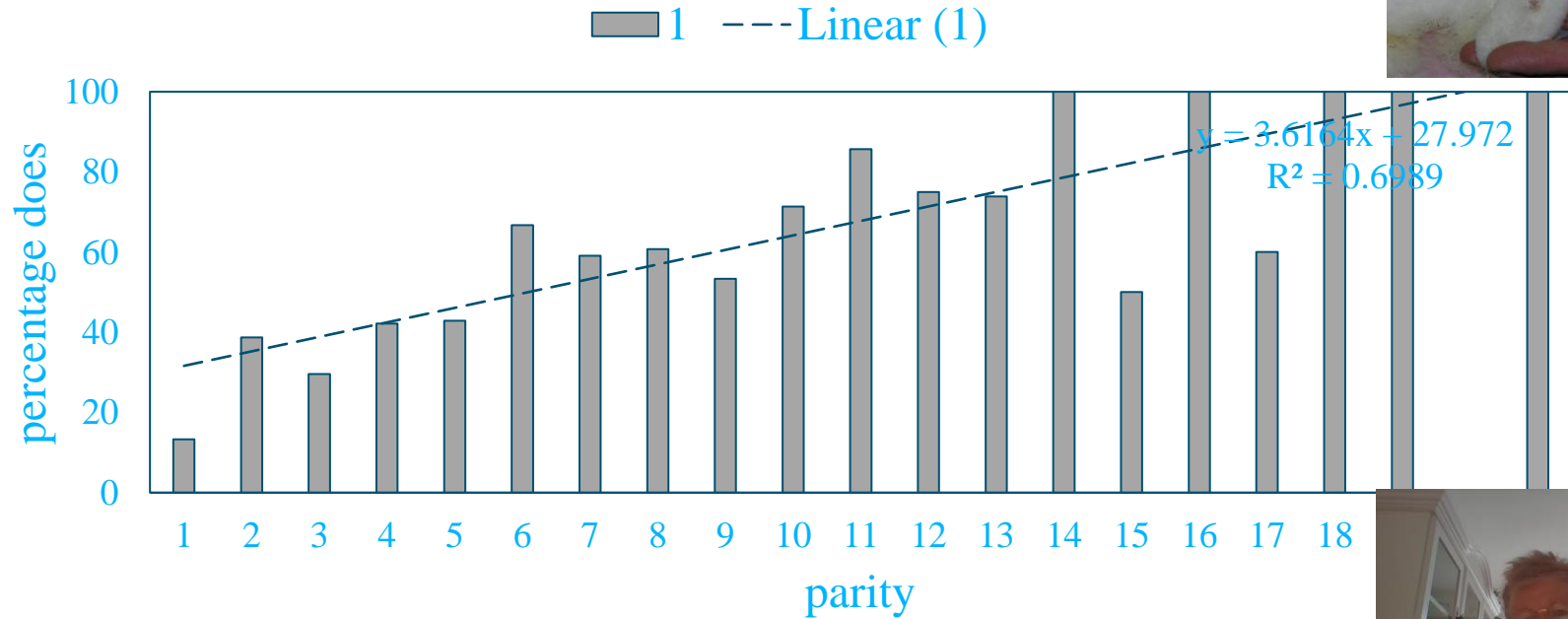
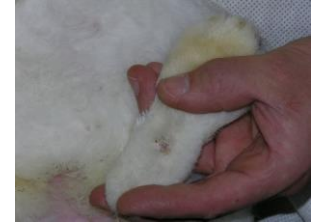Distribution of does according to parity



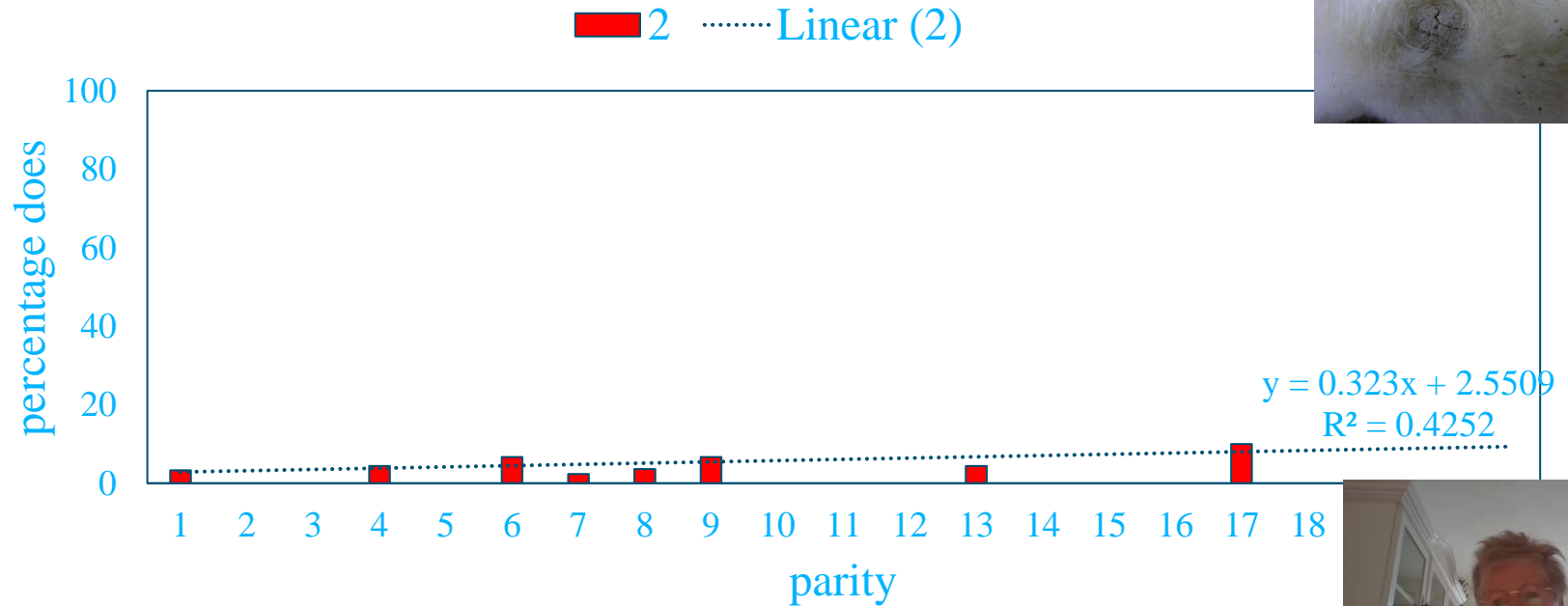
Footpad scores according to parity



Footpad scores according to parity



Footpad scores according to parity



Conclusions

- In NL plastic mats are effective in rabbit does:
 - Hyperkeratosis is often observed,
but no ulcerations
 - Hyperkeratosis increased with parity/age
- In meat rabbits pododermatitis was not observed

