



PROCEEDINGS OF THE 11th WORLD RABBIT CONGRESS

Qingdao (China) - June 15-18, 2016

ISSN 2308-1910

Session Reproduction

***Robert R., Bebin K., Loussouarn V., Dobe P., Gardan-Salmon D.,
Destombes N., Briens C.***

**PREGNANCY DIAGNOSIS: A NEW, NON-INVASIVE METHOD
TO ESTIMATE THE PROLIFICACY POTENTIAL
DURING RABBIT GESTATION.**

Full text of the communication

How to cite this paper :

*Robert R., Bebin K., Loussouarn V., Dobe P., Gardan-Salmon D., Destombes N., Briens C., 2016 - . Pregnancy diagnosis: a new, non-invasive method to estimate the prolificacy potential during rabbit gestation. *Proceedings 11th World Rabbit Congress - June 15-18, 2016 - Qingdao - China, 213-216.**



PREGNANCY DIAGNOSIS: A NEW, NON-INVASIVE METHOD TO ESTIMATE THE PROLIFICACY POTENTIAL DURING RABBIT GESTATION

Robert R.^{1*}, Bébin K.², Loussouarn V.¹, Dobe P.¹,
Gardan-Salmon D.², Destombes N.³, Briens C.²

¹ EUROLAP – Le Germillan - 35140 Gosné, France

² DELTAVIT Groupe CCPA- ZA du Bois de Teillay - 35150 Janzé, France.

³ TERRENA – La Noëlle - 44150 Ancenis, France.

*Corresponding author: raphael.robert@eurolap.fr

ABSTRACT

The aim of this study is to explore a new method for counting foetuses on day 15 of gestation and to compare this number with direct observation of embryonic vesicles after necropsy of these same does. This new non-invasive method uses a high-precision CT scanner coupled with multidimensional image analysis. Forty Hyla rabbits are scanned alive on day 15 of gestation, then autopsied to count the number of corpora lutea and embryonic vesicles. Image analysis makes it possible to accurately count the number of embryonic vesicles: 14.43 vesicles per doe visualised on the scanner versus 14.40 vesicles per doe on necropsy, i.e. a scan error of one vesicle per 577 observed. However, it is not possible to count the corpora lutea by scanning, or to examine the contents of the embryonic vesicles (empty or with delayed development), CT scanning can therefore be used to accurately quantify the number of implanted embryos and late foetal viability but not losses due to defective fertilisation and/or early embryo mortality. This remains an expensive technique at present, but offers interesting opportunities for reproductive and genetic studies since it keeps the animals alive.

Key words: Rabbit, gestation diagnostic, CT scanner.

INTRODUCTION

Prolificacy is one of the key factors in successful rabbit farming. In the field of research, it is therefore necessary to know and understand the components involved in this prolificacy, from ovulation to kindling. The chronological sequence of the various stages, from ovulation to kindling, is presented in figure 1 (Laborda-Vidal 2011, Llobat-Bordes 2012, Caron *et al.*, 2012). To gain a clearer understanding of embryo and foetus losses, follow-up of pregnancy using a non-invasive method would be required.

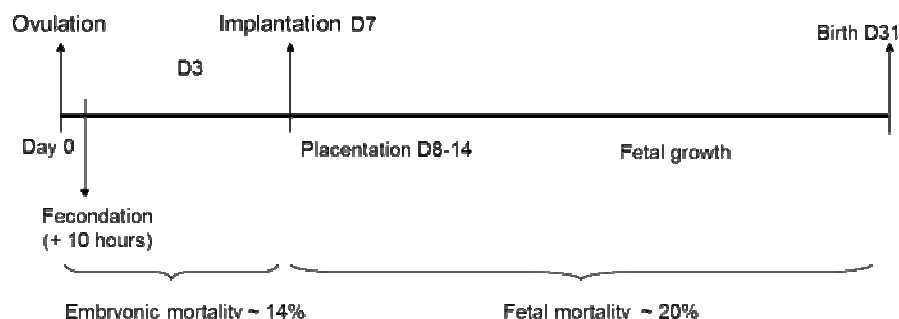


Figure 1. Embryo mortality during pregnancy in rabbits (Laborda-Vidal 2011 and Llobat-Bordes 2012)

A number of methods have already been tested today. Necropsy is a method that accurately and exhaustively characterises the development of embryos, foetuses and extraembryonic membranes at a determined stage. However, this method does not indicate the size of the litter at birth since the animals are sacrificed. Other methods have been tried and tested: endoscopy and ultrasonography. Endoscopy is useful to determine the

ovulation rate and implantation rate without affecting embryo survival and without sacrificing the rabbits (Theau-Clément and Bolet, 1987). It has also been used to study the relationship between the number of foetuses, the litter size and the weight of kits at birth (Bolet *et al.*, 1990). However, this is a surgical method requiring the rabbits to be anaesthetised. Ultrasonography was initially used for early pregnancy diagnosis (Tainturier *et al.*, 1986; Ypsilantis and Saratsis, 1999), and then to determine embryo and foetal development (Caron *et al.*, 2012; Chavatte-Palmer *et al.*, 2005; Layssol-Lamour *et al.*, 2009). This method is reliable for measurements on small numbers of foetuses, but less so for accurately counting a large number of foetuses (≥ 6 ; Chavatte-Palmer *et al.*, 2005) or differentiating their presence in the right or left uterine horns (Layssol-Lamour *et al.*, 2009). In addition, to perform ultrasonography, the animals have to be shaved and restrained on their backs.

The aim of this study is to offer a non-invasive alternative (X-ray CT scan, CT scan) to these methods for counting foetuses on day 15 of gestation and to compare this number with direct observation of embryonic vesicles after necropsy of these same does.

MATERIALS AND METHODS

Animals and insemination methods

Forty lactating multiparous Hyla rabbits were inseminated 11 days after kindling. Fifty-four hours before insemination, a subcutaneous injection of 25 IU of PMSG was administered. At the time of insemination, an injection of 0.8-1 μ g Buserilin (Product: Réceptal® Intervet MSD Santé Animale) was administered to trigger ovulation.

Feeding method and light

The females were fed *ad libitum* with the same feed (2,500 kcal DE (digestible energy), 17.5 CP (crude protein)).

Light stimulation was applied, with a switch from 12 to 16h of daily lighting, for 7 days before and 7 days after insemination. A gradual return to 16h was performed over 2 days at a rate of 2h/day.

CT scanner observations

On day 14 of gestation, the rabbits were weighed and palpated to make a first pregnancy diagnosis.

These 40 rabbits with uniform weights and a positive pregnancy diagnosis were scanned the following day, 15 days after insemination (S.A.R.L. IMAGE ET). The X-rays emitted by the scanner cross the organs and are stopped to variable degrees on the basis of the organs' density. This provides a 3D image after computer processing.

To go through the scanner, the rabbits were placed in an opaque wooden box (reassuring darkness) containing four individual cells, enabling four animals to be scanned simultaneously. Each cell is a confined space, limiting their movements as much as possible, since the animals must be immobilised during scanning. With the rabbits placed one behind the other, a CT scout (tracking radiography to produce the 4 acquisition fields) is performed first (Figure 2a). Then, 4 high-resolution spiral series (= 1 series of images for each doe) were performed to obtain thin-slice images of each animal (Figure 2b). Live image construction was performed in order to verify the immobility of the animals during the procedure. The average scan time for 4 does was 15 minutes. Finally, image analysis was performed by dual reading by 2 image analysts to compare opinions (3D image: Figure 2c).

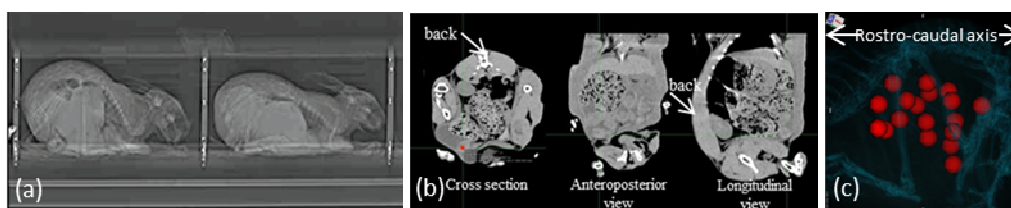


Figure 2. X-ray radiography of does: overall view (a), and slices (b); 3D view of the embryonic vesicles reconstituted by image analysis (c)

Sacrifice and necropsy of animals

Sacrifices were conducted by electronarcosis under veterinary supervision. On day 15 of gestation, the 40 does were transported to the DELTAVIT laboratory for necropsy in order to count and assess the viability of the foetuses. Different measurements were taken: number of corpora lutea enabling determination of the number of oocytes released, number of embryonic vesicles corresponding to the number of implanted embryos and number of viable and non-viable foetuses as shown in Figure 3.

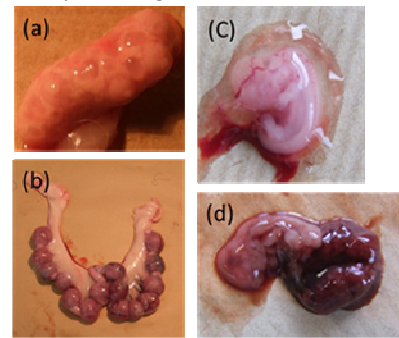


Figure 3. Illustrations of the observations performed on necropsy: ovary for counting of corpora lutea (a), isolated gestating uterus to identify and count embryonic vesicles (b), viable foetus on day 15 of gestation (c) and haemorrhagic vesicle and non-viable foetus on day 15 of gestation (d).

Statistical analysis

A Kruskal-Wallis non-parametric test was used to compare the counts made on the scan and after necropsy of the rabbits. The significance level is 5%.

RESULTS AND DISCUSSION

Image analysis makes it possible to visualise in 3 dimensions and accurately count the number of embryonic vesicles formed on day 15 of gestation. (Figure 2, c). Dual reading for analysis of the images revealed only one discrepancy for one vesicle (i.e. a total of 577 vs 578 embryonic vesicles, depending on the image analyst).

Following necropsy, 576 embryonic vesicles were counted, i.e. 1 or 2 vesicles less than on image analysis (i.e. 0.2%). These scan interpretation errors may be explained by confusion between an embryonic vesicle and a digestive artefact. In addition, the scan does not differentiate between vesicles containing a viable foetus, empty vesicles and those with a non-viable foetus. Only 10 vesicles were considered to be suspect on scanning, whereas after opening the vesicles in the laboratory, 39 vesicles were seen to be either empty or to contain a non-viable foetus (Table 1).

Observation of the average data per rabbit corroborates the overall analysis, i.e. that CT scanning can accurately detect the number of embryonic vesicles but does not detect empty vesicles or non-viable foetuses (Table 1).

Table 1. Comparison of the average number of implanted embryos (embryonic vesicles) and non-viable foetuses per doe on day 15 of gestation observed by CT scan or necropsy

	Embryonic vesicles		Suspect vesicles		Empty vesicles or non-viable foetuses	
	Mean	SD	Mean	SD	Mean	SD
CT scan	14.43	2.159	0.25	0.630		
Necropsy	14.40	2.318			0.975	1.343
<i>p</i>	0.989					

The analysis of the results of counting of the number of foetal vesicles for each doe depending of the used method, shows that for 82.5 % of females there is no difference (33 females on 40). There is a difference for 7 females (17.5 %) due to the difficulty differentiating by CT scan vesicles with a viable foetus *versus* with a no viable foetus (Table 2).

Table 2. Individual precision of vesicle count per doe

Differences Vesicles with CT scan – Vesicles with necropsy	-1	0	1	3
	Number of does	4	33	2
% of does	10	82.5	5	2.5

In comparison with ultrasonography, CT scanning is less restrictive in terms of the need to restrain animals (Chavatte-Palmer *et al.*, 2005), faster (15 minutes for 4 rabbits compared to 10 minutes per rabbit; Caron *et*

al., 2012) and more accurate for counting embryonic vesicles (Chavatte-Palmer *et al.*, 2005). However, ultrasonography provides numerous data concerning the development of the foetus and its organs (Caron *et al.*, 2012; Chavatte-Palmer *et al.*, 2005).

CT scanning cannot count the number of corpora lutea (ovulation rate) and empty vesicles or differentiate between viable and non-viable foetuses on day 15 of gestation (early foetal mortality). Only necropsy and endoscopy of the animals provide information concerning these litter size components.

CONCLUSION

This non-invasive method is accurate for determining the number of embryonic vesicles that have developed on day 15 of gestation. It is therefore possible to determine foetal viability after implantation by comparison with the total number of live kits, something that cannot be done using the necropsy method. However, this imaging method does not permit counting of corpora lutea, or qualification of the content of embryonic vesicles: therefore it cannot determine the ovulation rate and early embryonic viability, in contrast with necropsy or endoscopy. CT scanning, endoscopy and necropsy are thus complementary methods for studying prolificacy components: necropsy and endoscopy for the number of eggs released and assessment of embryonic losses following fertilization on day 15 of gestation, CT scanning to determine the number of embryos implanted and foetal viability after implanting. The choice of method must be considered on the basis of the research avenue targeted. At present, the medical imaging method remains expensive, but its main value lies in the fact that the animals are kept alive. CT scanning therefore has a role to play in cross-disciplinary studies (genetics, reproduction, nutrition, pathology, treatment, etc.) concerning prolificacy components.

ACKNOWLEDGEMENTS

We would like to thank C. Tavernier and Y. Richaudeau from IMAGE ET for their advice and expertise. We would also like to thank the team at the DELTAVIT laboratory for having performed the autopsies and the EUROLAP animal husbandry team at Belleville[®]/Vie for its assistance in the follow-up of the does.

REFERENCES

- Bolet G., Esparbie J., Falières J., 1990. Relations entre le nombre de fœtus par corneutérine, la taille de portée à la naissance et la croissance pondérale des lapereaux. *Annales Zootechnie*, 45, 185-200.
- Caron M., Bencharif D., Briand L., Tainturier D., 2012. Diagnostic et suivi de la gestation chez la lapine par échographie avec une sonde de 12.5 MHz. *Revue Méd. Vét.*, 163, 6, 309-315.
- Chavatte-Palmer C., Laigre P., Simonoff E., Chesne P., Challah M., Renard J.P., 2005. Caractérisation de la croissance foetale *in utero* par échographie chez la lapine. In: *11èmes Journées de la recherche cynicole*, Paris.
- Laborda-vidal P., 2011. Selection for ovulation rate in rabbits. *Tesis doctoral*. Universidad Politécnica de Valencia.
- Llobat-bordes D., 2012. Estudio de los factores materno-embrionarios que determinan la fertilidad y prolificidad en una línea de conejos seleccionada por velocidad de crecimiento. *Tesis doctoral*. Universidad Politécnica de Valencia.
- Layssol-Lamour C., Hurtaud J., Saleil G., Laperruque F., Tircazes A., Ruesche J., Bolet G., 2009. Suivi par échographie et sacrifice à J28 du développement embryonnaire et foetal dans deux lignées de lapins sélectionnées sur l'homogénéité du poids des lapereaux à la naissance. In: *13èmes Journées de la recherche cynicole*, Le Mans, 145-148.
- Tainturier D., Fieni F., Escoufflaire P., 1986. Diagnostic de la gestation chez la lapine par échotomographie. *Revue Méd. Vét.*, 137, 3, 163-167.
- Theau-Clement M., Bolet G., 1987. Mesure du taux d'ovulation par coelioscopie chez la lapine. *Reprod. Nutr. Develop.*, 27, 701-705.
- Ypsilantis P., Saratsis P., 1999. Early pregnancy diagnosis in the rabbit by real time ultrasonography. *World Rabbit Science*, 7, 2, 95-99.

=====