

IN VIVO MEASUREMENT OF PERIRENAL FAT BY MAGNETIC RESONANCE TOMOGRAPHY

KÖVER GY.¹, SORENSEN P.², SZENDRŐ ZS.¹, MILISITS G.¹

¹ Pannon Agriculture University, Faculty of Animal Science, 7401 Kaposvár, Po. Box 16, Hungary

² National Institute of Animal Science, Foulum, 8830 Tjele, Denmark


Abstract - An experiment using MR tomography were done involving 45 Pannon White rabbits of 12 and 16 weeks of age. Magnetic Resonance Imaging (MRI) was applied on the day before the slaughtering. The slices were taken in the coronal plane. The resulting pictures indicate that MRI provides very detailed slices. The volume of the fat deposit around the kidneys was collected from the MRI pictures. The data coming from the spin echo sequence based images and the weight of the perirenal fat measured in the slaughterhouse correlate with the r values of 0.93 and 0.94.

INTRODUCTION

Magnetic Resonance Imaging is one of the most important methods for analysing the body structure and composition of living humans and animals. This procedure of measurement is a non-invasive, highly sensitive method of viewing the body structure in subtle details. MRI is based on the T_1 and T_2 relaxation processes of the excited protons (H^1) in a strong magnetic field. The protons in different boundings have different relaxation processes and relaxation times (T_1 , T_2). As the water, the protein and the lipid contents vary from tissue to tissue so do the relaxation times (T_1 , T_2). Besides the water and fat have a strong effect on the relaxation parameters (T_1 , T_2). Therefore this method means a high chance in animal body composition analysis, similar to the revolution caused by the MR in human radiology.

There are two reason why the adipose deposits are important for the economy of the meat production. First, because of their total mass, they add to the cost of production. Secondly, because of their contribution to the quality of the carcass.

Figure 1 : The rabbit in the knee coil is going into the magnet of the MR tomograph

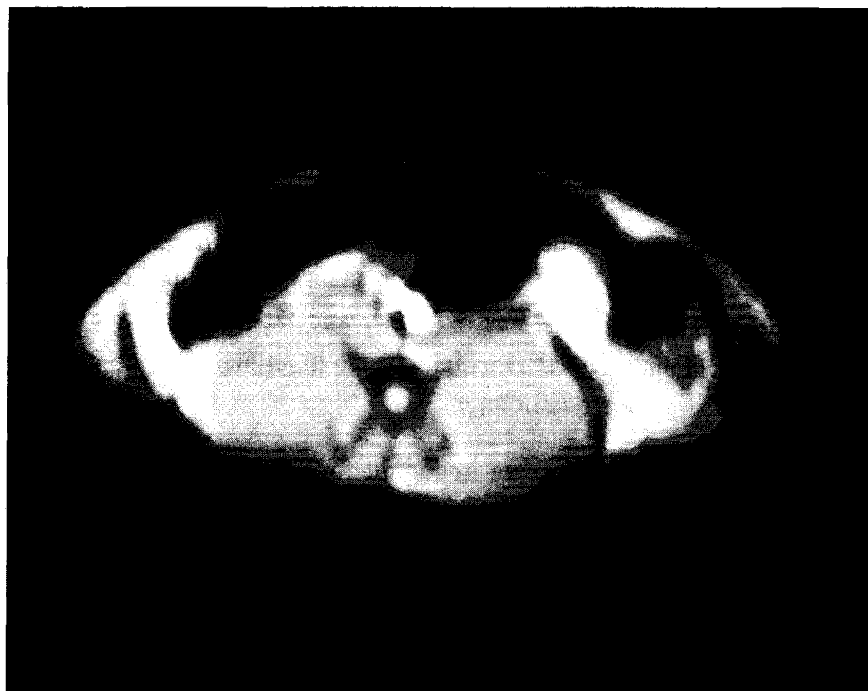

Thus it is interesting to study not only the overall development of deposits during growth, but also the relative development of the adipose deposits with different locations (VEZINET and PRUD'HON, 1975). The total fat content of the body and the carcass fatness can be estimated by the volume of the kidney fat (OUHAYOUN, 1978; BRUN and OUHAYOUN, 1988). The signals of body mobilization are induced in fat depots (MASOERO *et al.*, 1992). The perirenal fat content decreased during the first pregnancy of does (MILISITS *et al.*, 1996). The weight of the fat in lion and hind part were correlated with the weight of the fat in the carcass ($r = 0.69$ and 0.63 respectively; NIEDZWIADK, 1980). A significant positive relationship ($r = 0.59$) was determined between fat deposit content and intramuscular fat content by MAERTENS and DE GROOTE (1992).

In vivo measurement of the perirenal fat gives a good opportunity to follow the change of fat in rabbits during the fattening period, pregnancy and lactation. Our aim was to estimate the perirenal fat content by MRI.

MATERIAL AND METHODS

Figure 2 : Localising MR image in the axial plane. Gradient echo sequence was used



In this present project Pannon White rabbits were scanned in vivo in a Siemens Magnetom SP 63 1.5 Tesla whole body MRI scanner. 9 of the rabbits were scanned at the age of 12 week the other 36 of them were scanned at the age of 16 week. The group consisted of 30 males and 15 females. The average of the live weight of the animals was 3286g and ranged from 2620g to 4010g.

Before putting the rabbits in the MR tomograph they were starved for ten hours and anaesthetized. The reason of the anaesthetizing was to reduce the motion artefacts on the MR images. Rompun (containing Xylasin) was given to the animals. The amount of the drug given was 0.1 ml/kg.

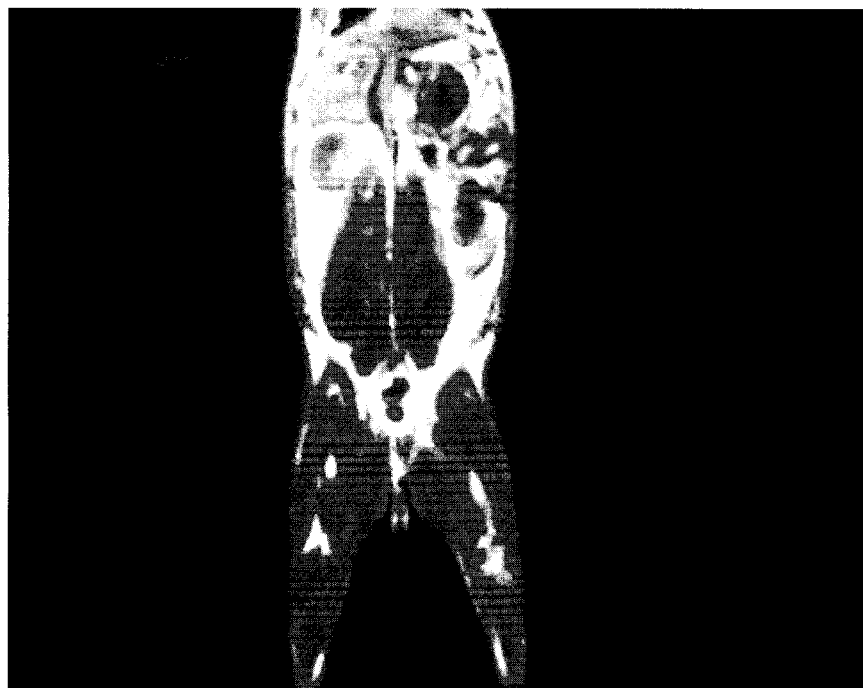
The rabbits were put into the tomograph in a special cradle lying on the belly, the legs were tied and straightened forward and backward (figure 1.).

After using gradient echo sequence in the axial plane for localization (figure 2.) spin echo sequence was used to take images in the coronal plane (figure 3.). All the images were taken with a knee coil using T₁ weighted spin echo sequence. The slices were 6 mm thick, covering the whole body. The other parameters of the applied sequence were:

- number of excitations: 3,
- time of repetition: 400 ms,
- time of echo: 15 ms.

The total time of acquisition depended on the number of slices necessary to cover the body. In one plane the total series could take about 5 - 6 minutes.

Figure 3 : The area of the kidney fat is measured on the spin echo images in the coronal plane.



As shown in figure 3 T₁ weighted spin echo sequence results in a very good picture quality with high details of the soft tissues. Due to inadequate anaesthetizing some animals started moving before finishing the MRI scanning which is why the coronal slices cannot be evaluated and these animals were excluded from the study. The MRI picture consists of 256x256 pixels, each with a numeric value. High value pixels are represented by white on the MR pictures and mean fat tissues. Pixels with lower values are represented with grey scale and mean other soft tissues, eg. muscle.

With the help of the MRPC (computer program, PANNON University, Diagnostic Centre, Kaposvár, by Kövér and Berényi) on a graphic work station the area of the fat tissues from a whole picture, or from a part of a picture can be taken. The MR picture is very rich in details of soft tissues. That is why drawing around the fat deposit of the kidney is possible.

The following data set were collected (table 1. and 2.):

- The total amount of kidney fat pixel area on the coronal pictures. The volume of the total fat can be approximated by summing these fat areas and multiplying the sum by the slice thickness (6 mm).
- The weight of the kidney fat from the slaughter house.

RESULTS AND DISCUSSION

Table 1 : Descriptive statistics and correlation between the MRI volume and the weight of the perirenal fat in the case of the 36 Pannon White rabbits, of 16 weeks of age.

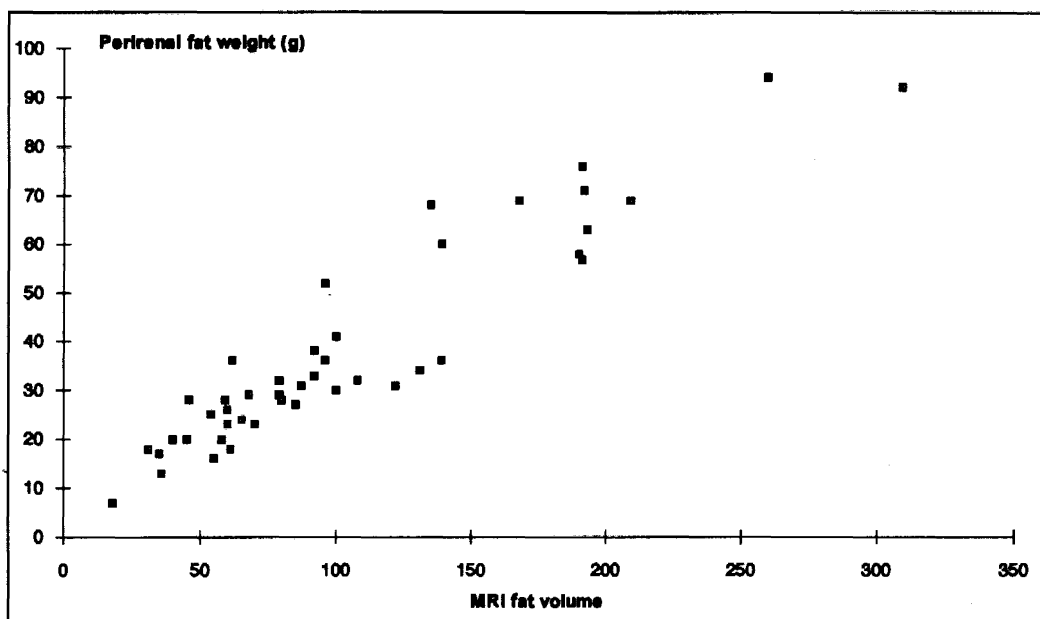
Traits	Mean	Std. dev.	Min	Max
Live weight (g)	3445	253	3020	4010
Fat weight (g)	42	21	16	94
Fat volume from the MR	115	65	31	309
Correlation between MR fat volume and fat weight	$r = 0.93$			

The in vivo MRI experiment resulted in the total volume of the kidney fat taken from the MR images. The applied sequence gave excellent quality of pictures in very high details. The volume of the kidney fat strongly correlates with the weight of the fat deposit around the kidney measured post mortem (figure 4.). The r values are 0.93 and 0.94. The method of scanning the rabbits with a magnetic resonance tomograph gives us the possibility to predict in vivo the weight of the perirenal fat with very high accuracy.

Table 2 : Descriptive statistics and correlation between the MRI volume and the weight of the perirenal fat in the case of the 45 Pannon White rabbits, of 12 and 16 weeks of age.

Traits	Mean	Std. dev.	Min	Max
Live weight (g)	3286	391	2620	4010
Fat weight (g)	37	21	7	94
Fat volume from the MR	103	65	18	309
Correlation between MR fat volume and fat weight	$r = 0.94$			

Figure 4 : Scatter plot, illustrating the strong relationship between the MRI volume and the weight of the perirenal fat in the case of the 45 Pannon White rabbit, 12 and 16 weeks of age.



REFERENCES

- BRUN J.M., OUHAYOUN J., 1988. Growth performance and carcass traits in three strains of rabbits and their two-way crosses. *4th World Rabbit Congress, Budapest, Vol 2*, 168-176.
- MAERTENS L., DE GROOTE G., 1992. Study of influence of slaughter weight on carcass yield and carcass composition of broiler rabbits. *Rev. Agric.*, 45.1, 59-70.
- MASONERO G., RICCONI L., BERGOGLIO G., NAPOLITANO F., 1992. Implications of fasting and transport for a high quality rabbit meat product. *5th World Rabbit Congress, Corvallis, Proc. B*, 841-874.
- MILISITS G., ROMVARI R., DALLE ZOTTE A., XICCATO G., SZENDRO ZS., 1996. Determination of body composition changes of pregnant does by x-ray computerised tomography. *6th World Rabbit Congress, Toulouse (in press)*
- NIEDZWIADK S., 1980. Using regression equations to determine the meat, bone and fat content of White New Zealand rabbit carcasses. *3th World Rabbit Congress, Rome, Vol II*, 585-594.
- OUHAYOUN J., 1978 Etude comparative de races de lapins different par le poids adulte. These, Academie de Montpellier
- VESINET A., PRUD'HON M., 1975. Evolution of various adipose deposits in growing rabbits and sheeps. *Anim. Prod.*, 20, 363-370.

Mesure in vivo du gras périrénal par des images de résonance magnétique - Une expérience par tomographie a été effectuée sur 45 lapins Pannon White d'un âge de 12 à 16 semaines. Les images de Résonance Magnétique (MRI) ont été faites le jour avant l'abattage. Les couches ont été prises d'un plan coronal. Les images reçues indiquent que l'MRI donne des couches bien détaillées. Le volume du gras déposé autour des reins a été enlevé de l'image MRI. Les Données issues du "spin écho" ont servi de base pour des images, et la corrélation du poids du gras périrénal mesuré à l'abattoir est de 0.93, 0.94 à leur valeur.